

Inferior Oblique Surgical Anatomy

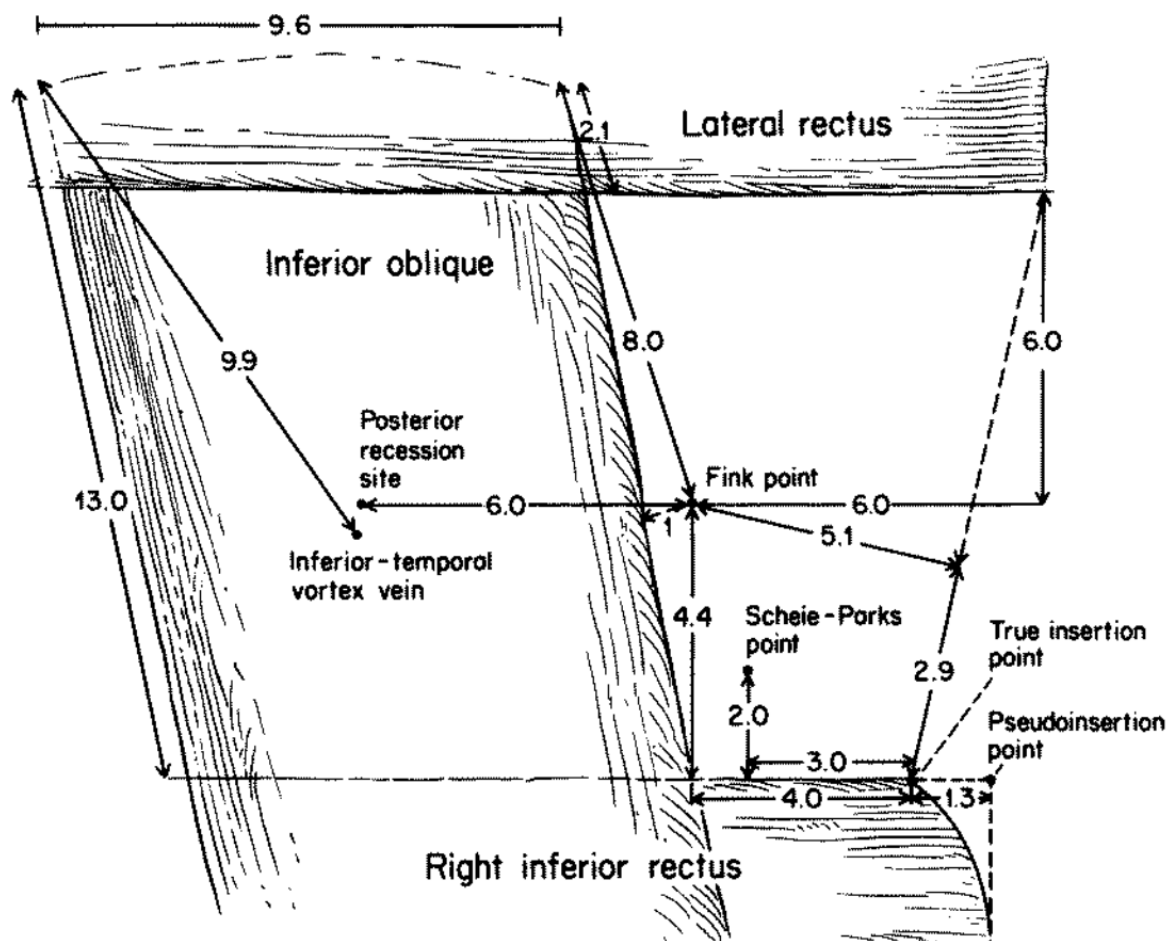


Figure 34-1. Anatomic diagram of the relationship of the inferior oblique muscle to nearby structures. (From Apt L, Call NB: Inferior oblique muscle recession. *Am J Ophthalmol* 1978;85:95. Reprinted with permission of Ophthalmic Publishing.)

Strabismus Surgery

From: <https://www.childrenseye.org/wiki/> - Children's Eye Wiki

Permanent link: https://www.childrenseye.org/wiki/doku.php?id=inferior_oblique_surgical_anatomy

Last update: 2017/01/16 15:33

