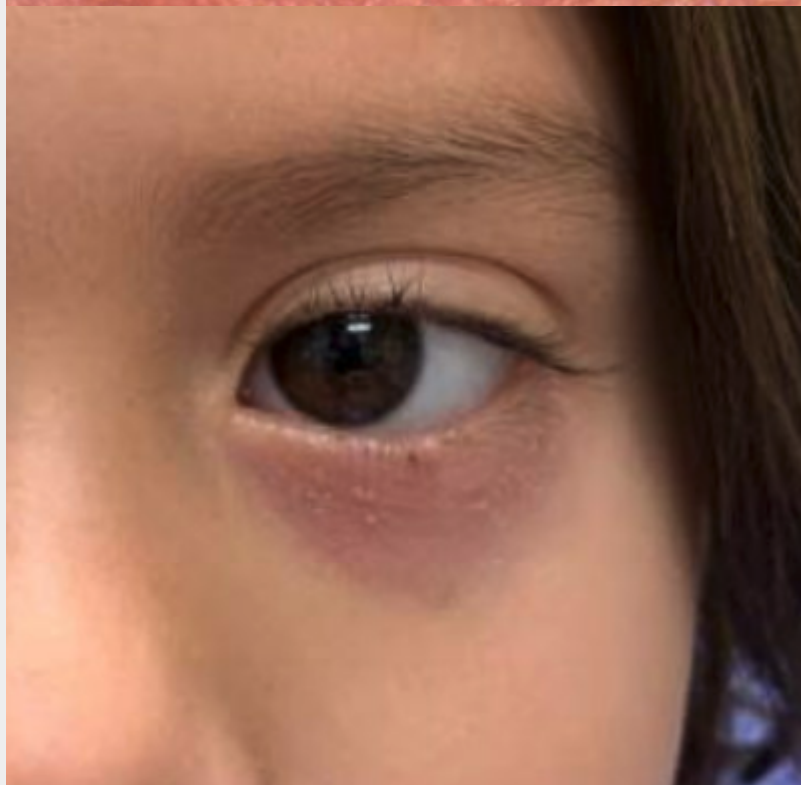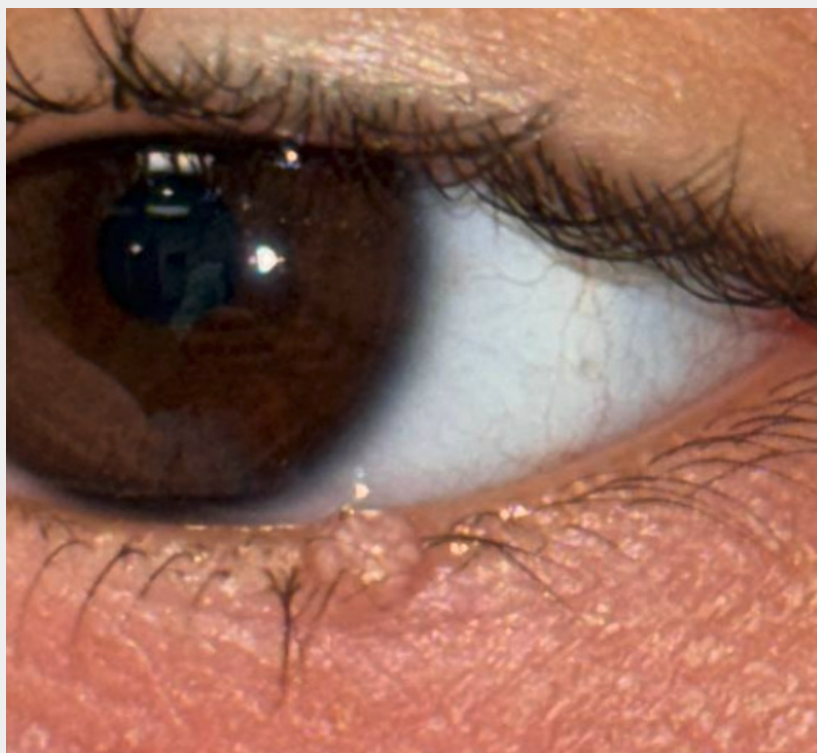
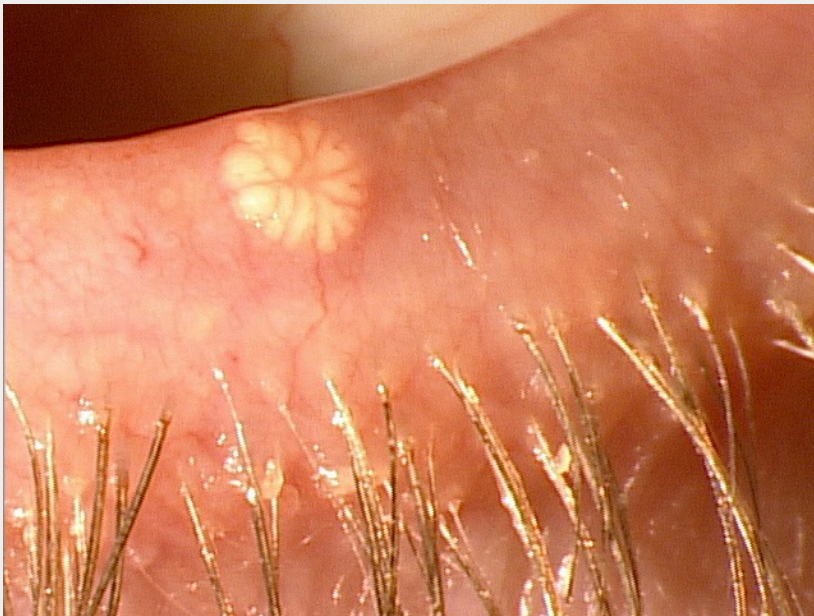


# Molluscum contagiosum

- A pox virus that infects children frequently
- Usually self limited but can become persistent
- If involves the eyelid can lead to conjunctivitis and keratitis
- Most treatments for non-periocular infections involve toxic substances that are not ideal for eyelid skin or inadvertent contact with ocular surface



From the clinics of Scott Larson, MD



<http://www.eyedolatryblog.com/2016/01/theres-bump-on-my-eyelid-molluscum.html>

## Periocular Treatment

- Incision and Curettage
  - should try to curette all lesions not just those on the eyelids otherwise the child may re-innoculate their eye from an existing lesion
- Topical adapalene 0.1% gel
  - an over the counter treatment for acne
- Clear nail polish

## Resources

- [Topical adapalene for the treatment of follicular conjunctivitis due to peri ocular contagiosum in children. Yi JS et al. AJO Case Reports 2022;25:101335](#)

From:

<https://childreneye.org/wiki/> - **Children's Eye Wiki**

Permanent link:

[https://childreneye.org/wiki/doku.php?id=molluscum\\_contagiosum](https://childreneye.org/wiki/doku.php?id=molluscum_contagiosum)

Last update: **2025/03/13 15:52**

