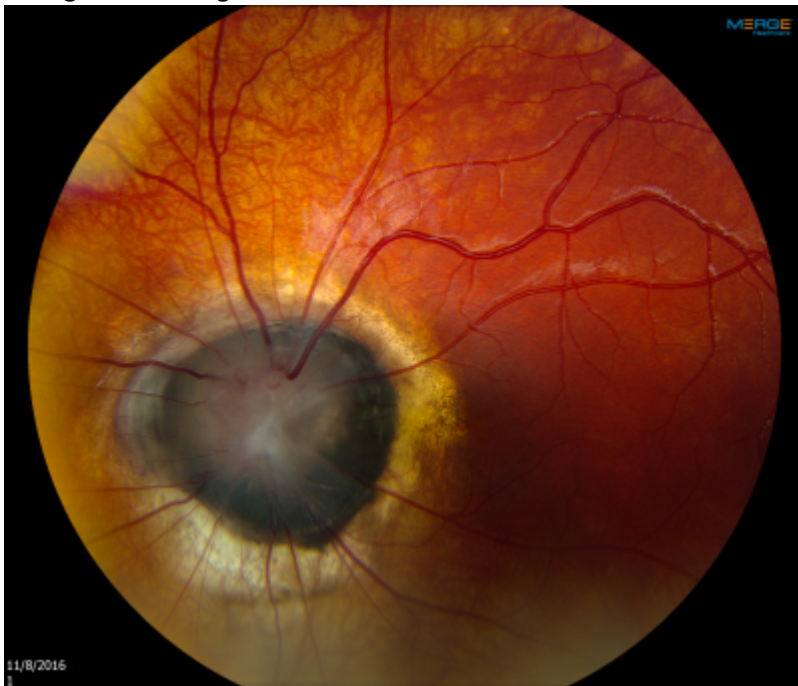


Morning Glory Disc

a.k.a Morning Glory anomaly

Appearance

Large optic nerve with dysplasia and filled with glial tissue. The nerves emanate from the disc margin in straight lines



Resembles the Morning Glory Flower



Associations

- Basal Encephalocele
- Moya Moya
- Other Brain structural or vascular abnormalities

From:

<https://childreneye.org/wiki/> - **Children's Eye Wiki**

Permanent link:

https://childreneye.org/wiki/doku.php?id=morning_glory_disc

Last update: **2016/11/09 16:38**

