

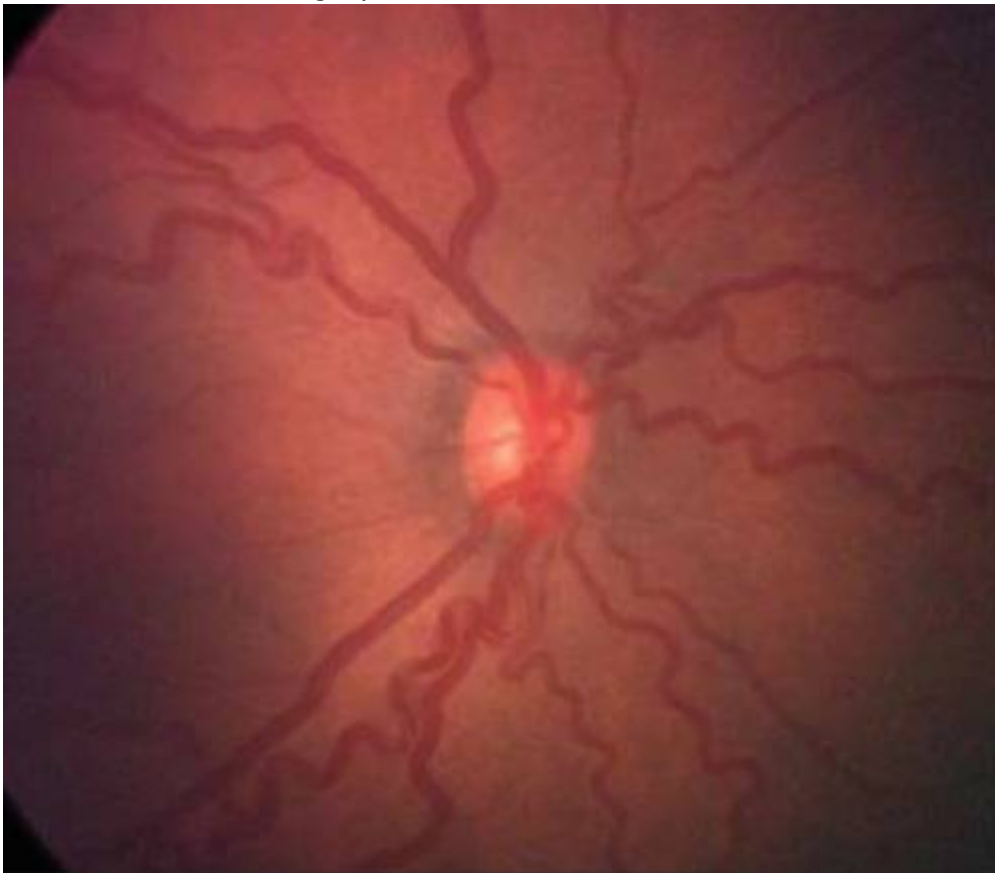# Retinopathy of Prematurity

## Plus

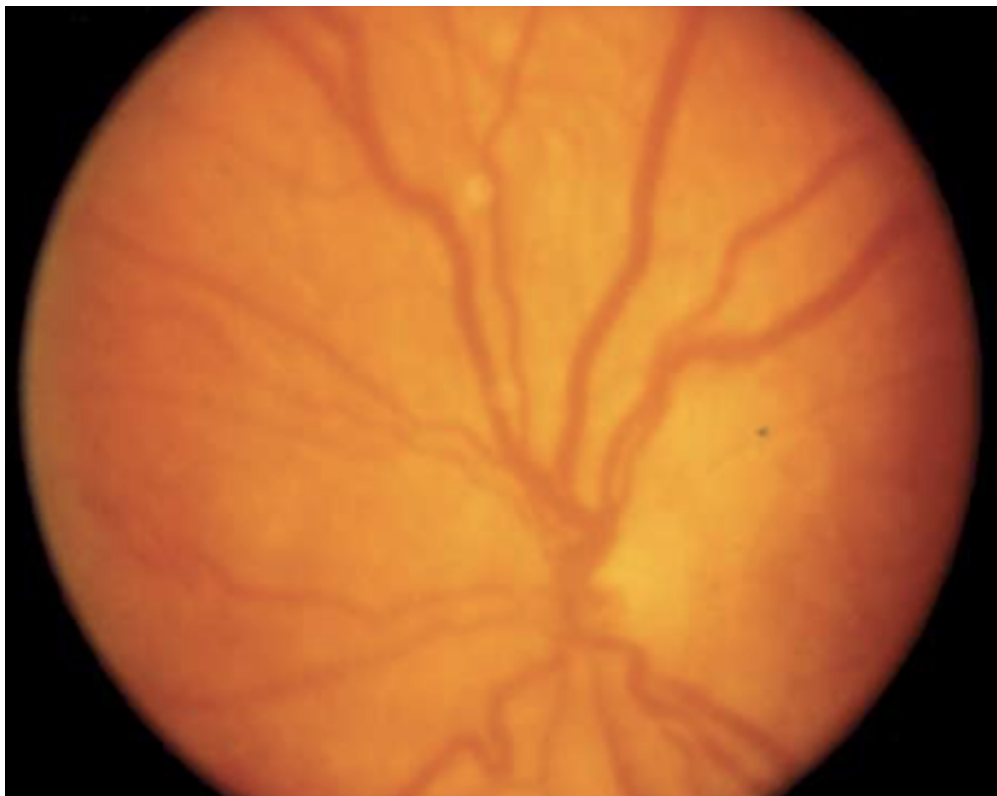
- Assessed at the optic nerve
- Use a 20D lens
- 2 quadrants of dilation and tortuosity

## Standard Photographs

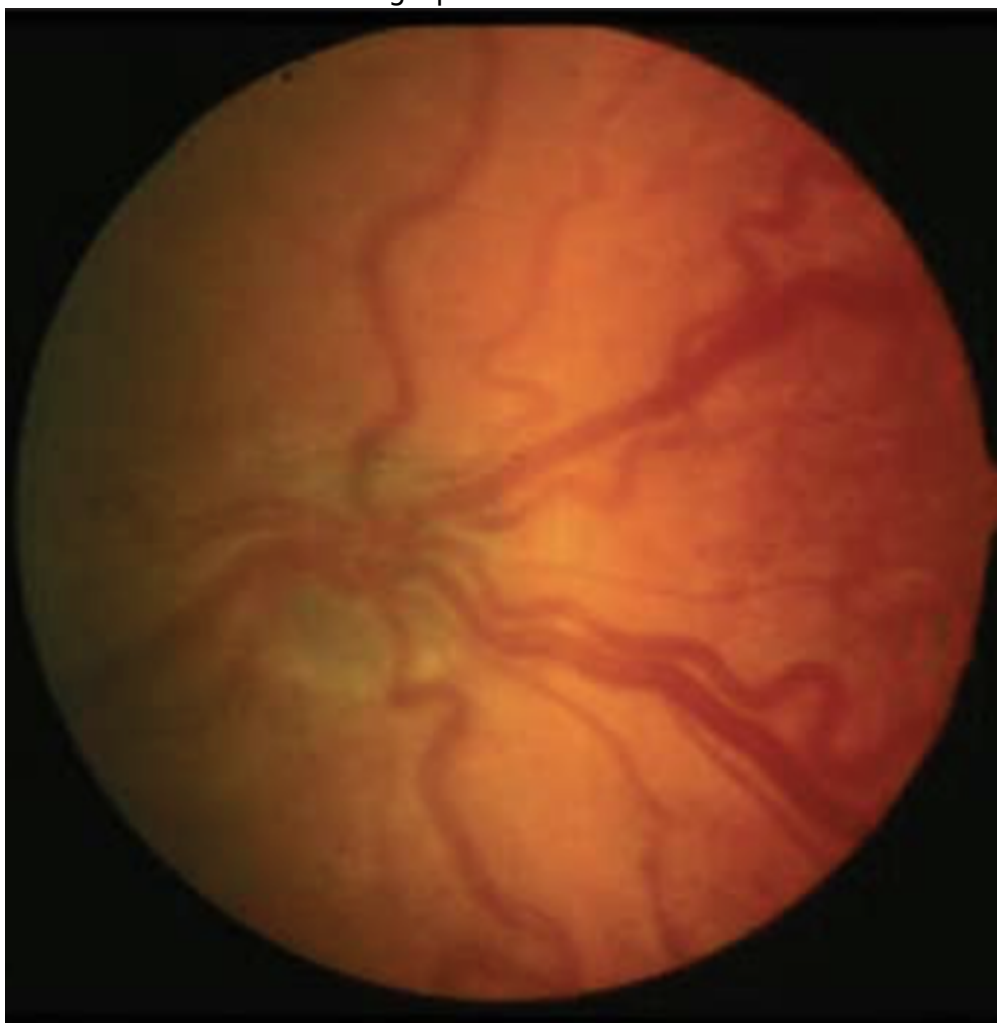
- Recommended Photograph



- ETROP Standard Photograph



- CRYO-ROP Standard Photograph



rop

From:

<https://childreneye.org/wiki/> - **Children's Eye Wiki**

Permanent link:

[https://childreneye.org/wiki/doku.php?id=retinopathy\\_of\\_prematurity](https://childreneye.org/wiki/doku.php?id=retinopathy_of_prematurity)

Last update: **2023/02/07 10:12**

