



## Major review

## Current management of Coats disease

Eric J. Sigler, MD<sup>a,b,\*</sup>, John C. Randolph, MD<sup>a,b</sup>, Jorge I. Calzada, MD<sup>a,b</sup>,  
Matthew W. Wilson, MD<sup>b,c</sup>, Barrett G. Haik, MD<sup>b,c</sup>

<sup>a</sup>Division of Vitreoretinal Surgery, Charles Retina Institute, Memphis, Tennessee

<sup>b</sup>Department of Ophthalmology, Hamilton Eye Institute, University of Tennessee Health Science Center, Memphis, Tennessee

<sup>c</sup>Ocular Oncology Division, St. Jude Children's Research Hospital, Memphis, Tennessee

## ARTICLE INFO

## Article history:

Received 5 December 2012

Received in revised form

19 March 2013

Accepted 19 March 2013

## Keywords:

Coats disease

type 1 idiopathic macular

telangiectasia

intravitreal bevacizumab

Leber multiple miliary aneurysms

retinal vascular disease

## ABSTRACT

Since its original description in 1908, Coats disease has been recognized as an idiopathic cause of severe vision loss with a remarkable diversity in clinical presentation and morphology. Key clinical and imaging variables are helpful in differentiating Coats disease from life-threatening malignancies, and proper management revolves around a thorough knowledge of the differential diagnosis. Despite significant advancement in scientific understanding of the disease process and clinical spectrum, the underlying etiology remains obscure, and both primary and secondary forms are recognized. With the development of anti-VEGF therapy, vitreoretinal specialists have a new, effective adjunct to the clinical management of exudates, macular edema, and serous retinal detachment. We highlight the history, diagnostic challenges, evolving clinical spectrum, and current management of Coats disease.

© 2014 Elsevier Inc. All rights reserved.

## 1. Introduction

In 1908, George Coats described first described a series of patients with a unique ocular disorder manifesting as retinal telangiectasis with massive intraretinal and sub-retinal exudation.<sup>21</sup> Coats disease is recognized as a cause of impaired vision, leukocoria, retinal telangiectasis, and exudation in both children and adults. Considerable progress has been made over the past century in understanding the incidence, morphology, patient characteristics, and natural history of disease; the precise underlying etiology,

however, remains unknown. The condition is probably congenital (based on frequent onset in infancy) but nonfamilial, usually not associated with systemic disease, occurs most commonly unilaterally in young males, and may be classified based on morphology.<sup>107</sup> The clinical spectrum of Coats disease (Fig. 1) is broad, ranging from asymptomatic perifoveal telangiectasis, such as that seen in type 1 idiopathic macular telangiectasia,<sup>16,41,107,135</sup> to total exudative retinal detachment with poor visual prognosis,<sup>13,51,85,107</sup> and may progress to neovascular glaucoma with eventual phthisis bulbi.<sup>51,107</sup>

There are no conflicts of interest or financial interests for the authors regarding the material presented in this report.

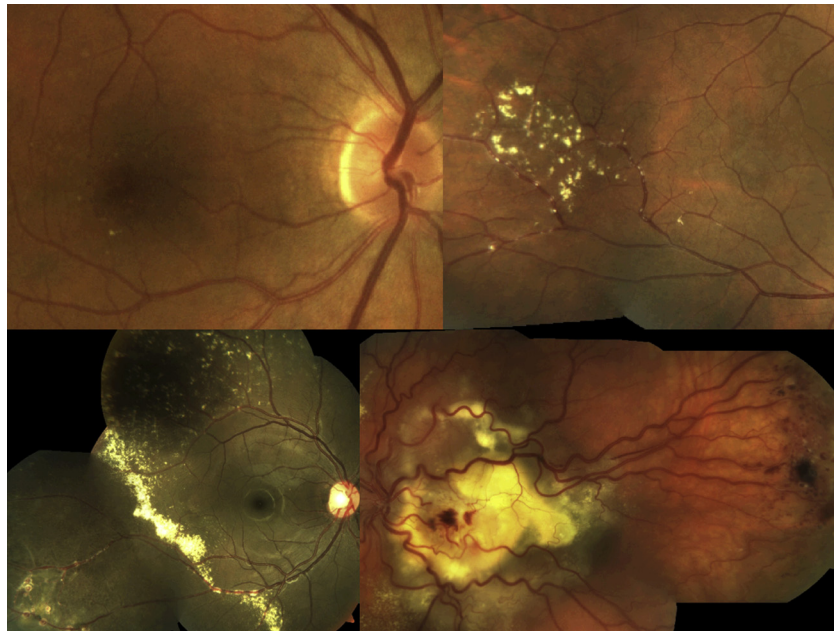
Supported in part by an unrestricted grant from Research to Prevent Blindness Inc., New York, NY, and The Ayers Foundation, Parson, TN.

\* Corresponding author: Eric J. Sigler, MD, Charles Retina Institute, 6401 Poplar Ave., Suite 190, Memphis, TN 38119.

E-mail address: [ejsigler@gmail.com](mailto:ejsigler@gmail.com) (E.J. Sigler).

0039-6257/\$ – see front matter © 2014 Elsevier Inc. All rights reserved.

<http://dx.doi.org/10.1016/j.survophthal.2013.03.007>



**Fig. 1 – Clinical Spectrum of Coats disease. Idiopathic macular telangiectasia type 1, or early development of moderate sized aneurysmal dilations in the temporal macula associated with scant exudate (upper left); temporal mid-peripheral exudate associated with telangiectatic retinal capillaries (upper right); diffuse exudate associated with inferotemporal telangiectatic vessels and focal extra-macular serous retinal detachment (lower left); total macular detachment with massive subretinal exudate and tortuous vasculature (lower right).**

## 1.1. History

### 1.1.1. Coats' observations

George Coats' original description of the disease was based primarily on histopathologic examination of enucleated eyes and identified retinal vascular aneurysms, arteriovenous malformations, intra- and subretinal hemorrhages, and exudates. Coats categorized eyes with these characteristic morphologic findings into three groups: Group I demonstrated massive subretinal exudate alone, group II consisted of eyes with massive subretinal exudate, intra- and subretinal hemorrhage, and retinal vascular dilatations, and group III included eyes with subretinal exudate and retinal arteriovenous malformations. Von Hippel later identified group III as a separate entity, angiomatosis retinae,<sup>76,129</sup> which led to the exclusion of this group from the spectrum of Coats disease. Coats also observed a mononuclear cellular infiltrate in many specimens, leading to early theories that the disorder was an infectious or inflammatory process.<sup>60</sup>

### 1.1.2. Leber's and Reese's observations

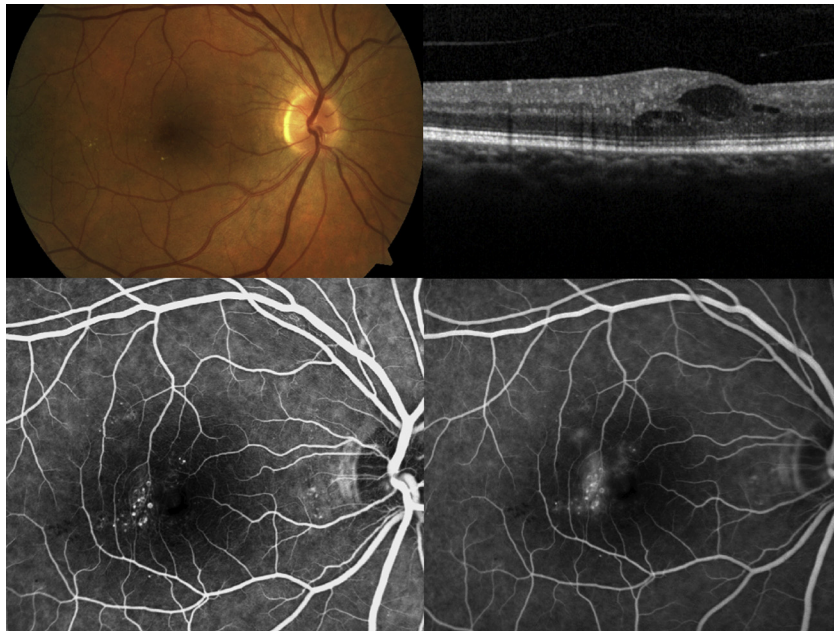In 1912, Theodor Leber described a disorder with similar retinal vascular abnormalities to Coats disease, but without massive subretinal exudate, hemorrhage, and serous retinal detachment.<sup>74</sup> This became known as Leber multiple miliary aneurysms, and Leber concluded that this entity was probably an earlier or less severe form of the disease previously described by Coats.<sup>73</sup> Reese observed patients with the clinical appearance described by Leber who eventually progressed to

a Coats-like clinical picture, and further reinforced the notion that the two entities were part of the same clinical spectrum.<sup>96</sup> The retinal vascular anomalies described by Leber and Reese are now usually considered as part of the range of clinical morphology present in Coats disease (Fig. 2), most recently termed "type 1 idiopathic macular telangiectasia".<sup>12,33,54,135</sup>

## 1.2. Demographics and clinical presentation

Coats disease affects males more frequently than females, with a ratio of 3:1 or more,<sup>12,33,107</sup> and the disorder is unilateral in greater than 75% of cases.<sup>12,33,107</sup> There have been no ethnic or geographic associations. Coats disease occurs as early as 3–4 months of age<sup>28</sup> and may be a congenital retinal vascular malformation,<sup>16,33,60</sup> although this has not been specifically documented at birth.

Coats frequently presents in childhood with decreased vision, leukocoria, or strabismus. Between 60% and 70% of cases present in the first decade of life. Adults may present with either symptoms identical to those present in children<sup>9</sup> or a milder form of disease with predominantly macular vascular anomalies such as those seen in type 1 idiopathic macular telangiectasia (Fig. 2). Thus the spectrum of clinical presentation may range from severe childhood exudative retinal detachment with leukocoria, strabismus, and poor vision to asymptomatic vascular anomalies in an adult. Although painless unilateral vision loss, leukocoria, or strabismus in a young male is the typical clinical presentation, bilateral cases and advanced disease with neovascular glaucoma and eye pain do occur.



**Fig. 2 – Macular edema in early Coats disease, or type 1 idiopathic macular telangiectasia. Small to moderate-sized aneurysmal dilations are present in the temporal macula with scant exudate (upper left); optical coherence tomography through the fovea reveals intraretinal cysts (upper right); mid phase fluorescein angiogram demonstrates characteristic aneurysmal dilations (lower left) which leak on recirculation phase images (lower right).**

## 2. Basic science

### 2.1. Histopathology

In the current era of early disease recognition and treatment, enucleation and the opportunity to examine pathologic specimens has become less common. Coats' early description, based on enucleated eyes, demonstrated many characteristic features: subretinal exudate, a mononuclear cellular infiltrate, and prominent cholesterol crystals.<sup>21,30</sup> Histologically, Coats disease frequently displays foam or "ghost cells" (histiocytes) in the inner retinal layers<sup>123</sup> and glial proliferation.<sup>31,127</sup> Specimens may demonstrate fibrinous subretinal exudate with dense cellular reaction, predominantly consisting of lipid and/or pigment-laden macrophages (Fig. 3).<sup>18,21,31,37,62,69</sup> Hemosiderin and pigment are frequently present within macrophages, and retinal pigment epithelial cells often exhibit fibrous metaplasia,<sup>18,31,70</sup> particularly following photocoagulation.<sup>62</sup> Electron microscopy demonstrates diffuse thickening of retinal capillary adventitia and areas of total absence of pericytes and vascular endothelium.<sup>125,127,134</sup> Although calcification is not common, late-stage disease may lead to diffuse retinal disorganization and potentially calcification by osseous metaplasia.<sup>102</sup>

### 2.2. Genetics

The exact molecular mechanisms underlying Coats disease remain to be elucidated. Several candidate gene mutations are described, including the Norrie disease protein (NDP),<sup>10,109</sup> CRB1,<sup>23,26</sup> and PANK2.<sup>115</sup> Mutations in NDP, the gene encoding for the secreted protein Norrin (a Wnt signaling pathway

protein) is associated predominantly with bilateral congenital retinal vasculopathies such as Norrie disease<sup>133</sup> and X-linked familial exudative vitreoretinopathy.<sup>10</sup> Norrin is a ligand for the Frizzled-4 receptor, but unlike familial exudative vitreoretinopathy, Coats disease does not appear to be associated with mutations in Frizzled-4.<sup>97</sup> Deficiency in Norrin has been associated with a mother with unilateral Coats disease who had a son with Norrie disease.<sup>10</sup>

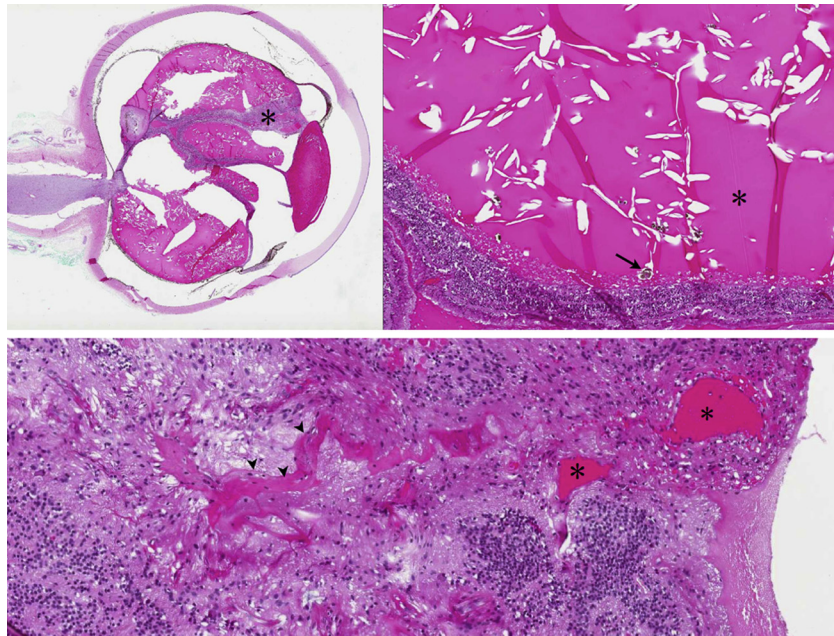
Cremers<sup>23</sup> and den Hollander<sup>26</sup> have recently demonstrated mutations in CRB1, a transmembrane protein that localizes to the brain and retina, in a majority of patients with inherited retinal disease that include a Coats-like retinopathy. CRB1 mutations do not, however, appear to be associated with classic Coats disease without retinitis pigmentosa.<sup>26</sup> A somatic mutation<sup>10</sup> is a compelling hypothesis given the congenital, non-familial, and unilateral features of the disease. A Coats-like retinal phenotype has additionally been described in both syndromic<sup>66</sup> and isolated retinitis pigmentosa<sup>66,116</sup> and with facioscapulohumeral dystrophy,<sup>49,124</sup> Senior-Loken syndrome,<sup>100</sup> and several other isolated cases.

## 3. Morphology and clinical spectrum

### 3.1. Ophthalmoscopy and fundus photography

#### 3.1.1. Anterior segment findings

The cornea, iris, lens, and vitreous are typically unaffected in early Coats disease.<sup>107</sup> Advanced stages may include ischemic anterior segment sequelae, including cataract, iris neovascularization, aqueous cellular reaction, flare, and neovascularization of the angle. Therefore, all patients with Coats



**Fig. 3 – Coats disease histopathology. Hematoxylin and eosin stain. Whole-eye specimen demonstrates total exudative retinal detachment in this eye enucleated for severe refractory neovascular glaucoma (upper left, 2× magnification). Magnified view of superior subretinal region demonstrating cholesterol crystals (asterisk) and pigment-laden macrophages (arrow, upper right, 10× magnification). Magnified view of peripheral retina demonstrates dilated vascular channels (arrowheads) with terminal spaces (asterisk, lower panel, 25× magnification).**

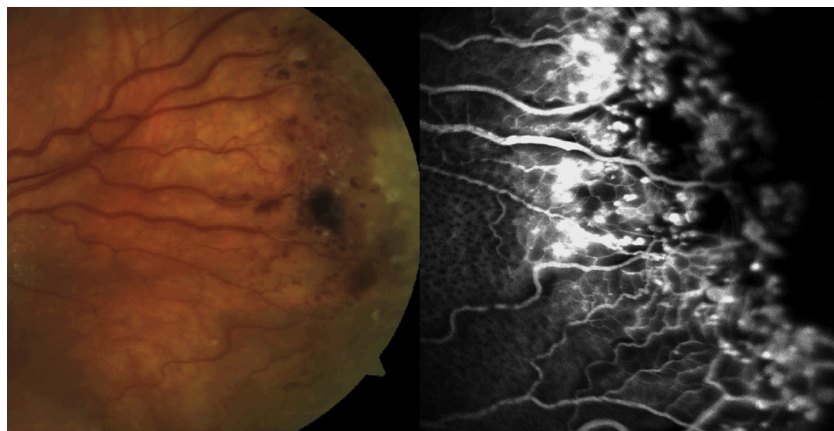
disease and elevated intraocular pressure require a complete gonioscopic evaluation. Anterior segment findings typically indicate more severe disease and predict worse visual outcome and a poor prognosis for globe salvage.<sup>51,107</sup> Anterior chamber and anterior vitreous cells are typically absent in Coats disease, and their presence therefore requires the consideration of an inflammatory etiology.

### 3.1.2. Posterior segment findings

In early disease (stage 1), telangiectasis and other vascular abnormalities develop in the retinal capillary network,

predominantly in the temporal macula and mid-periphery. Affected vessels exhibit irregular enlargement and associated aneurysmal dilations (Leber military aneurysms) on terminal vessels (Figs. 2 and 4).<sup>62,80,125,127</sup> These aneurysmal dilations, most commonly found surrounding areas of capillary dropout, tend to be radially oriented.<sup>33</sup>

Vascular abnormalities within the macula and periphery may result in progressive retinal edema and the accumulation of lipid exudates. When exudate accumulates in Henle's layer (parafoveal outer plexiform layer), a macular star develops. Macular edema from posterior or peripheral



**Fig. 4 – Vascular morphology in Coats disease. Fundus photography demonstrating temporal mid-peripheral sacular vascular aneurysms with tortuous, telangiectatic capillaries (left); fluorescein angiography demonstrating characteristic “light bulb” aneurysms, telangiectatic vasculature, and peripheral segmental nonperfusion (right).**

vascular leakage is a common cause of visual loss in Coats disease. In the posterior pole, subretinal accumulations of exudate may develop, forming yellow-white mounds and broad sheets of lipid material primarily composed of cholesterol (Fig. 5).<sup>30,107</sup> Longstanding subretinal exudates may exhibit superficial crystalline deposits.<sup>30</sup> Retinal blood vessels overlying patches of exudate may gradually become masked and undergo gliotic sheathing<sup>56,127</sup> as the mass of exudate increases. Retinal pigment epithelial cells that proliferate and migrate into the subretinal space and undergo fibrous metaplasia<sup>18,31</sup> have been associated with subretinal fibrous proliferation and resultant retinal detachment.<sup>79,85</sup>

Exudate most commonly occurs in the temporal macula and mid-periphery.<sup>33,107,135</sup> If the exudate involves a full retinal quadrant, a partial serous retinal detachment may ensue. The extent of serous detachment increases as the vascular and exudative components of the disorder proceed, until a total retinal detachment overlying a yellow-green subretinal mass results.<sup>51</sup> In few patients, the detachment spontaneously regresses before neovascular complications arise.<sup>19,27</sup> Secondary complications include uveitis, glaucoma, and cataract.<sup>45,54,107</sup> The choroid and sclera appear to be unaffected by the primary pathology of Coats disease.

The vitreous usually remains clear unless hemorrhage, neovascularization, massive leakage, or retinal breaks are present. Vitreoretinal traction, fibrosis, or proliferative vitreoretinopathy are rare<sup>107</sup>; epimacular membrane may be more common than previously recognized, however.<sup>63,108</sup> Peripheral fibrosis is seen with increasing frequency following intravitreal anti-VEGF agents<sup>95</sup> or cryotherapy<sup>43,95</sup> (Fig. 6). Macular fibrosis, which describes the macular intraretinal and subretinal fibrotic scar (Fig. 7) occurs as a consequence of long-standing exudate and choroidal neovascularization<sup>63,107</sup> and portends a worse visual prognosis.<sup>107</sup> This was recognized as a choroidal fibrotic mass in Coats' original description.<sup>21</sup> Preretinal fibrosis and vitreoretinal traction can be helpful differentiating features in

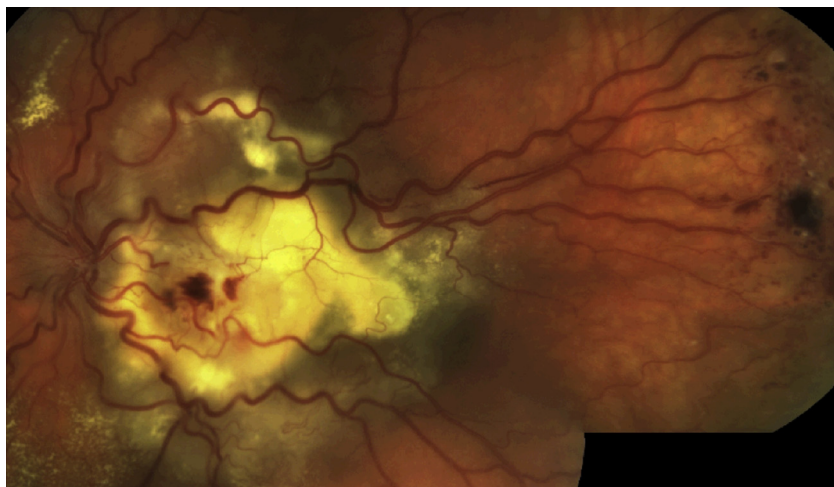
disorders with a Coats-like clinical picture, such as vasoproliferative tumor,<sup>72,103</sup> and their presence warrants consideration of additional diagnoses.

### 3.2. Ultrasonography

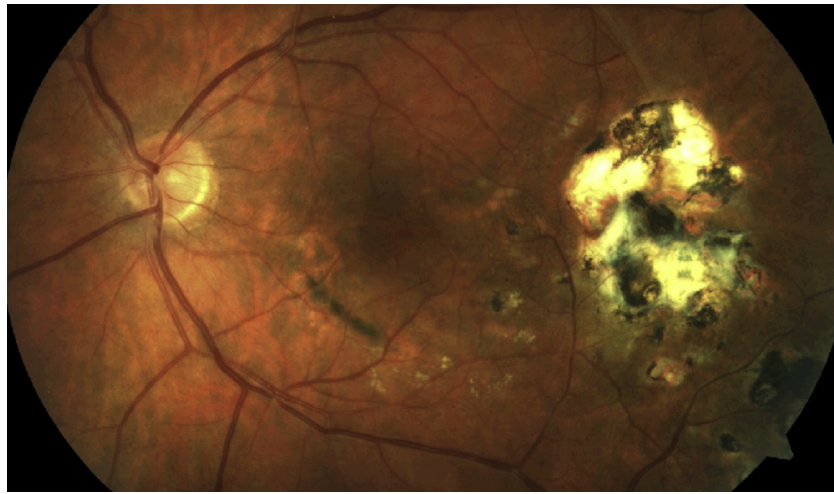
Ophthalmic B-scan ultrasonography is useful, especially in clinical situations where posterior segment examination is limited by media opacity or poor patient cooperation. Ultrasonography can confirm the disease extent and absence of a choroidal mass lesion in Coats disease.<sup>51</sup> Typical findings include relatively immobile, serous retinal detachment contiguous with the optic nerve head, hyperreflective masses of exudate, or clear subretinal space without significant choroidal thickening or vitreoretinal traction.<sup>51,107</sup> The presence of calcification, indicating a potential malignancy, can also be assessed.

### 3.3. Angiography

Fluorescein angiography facilitates early or peripheral detection of vascular abnormalities in stage 1 disease.<sup>68,107,125</sup> Characteristic findings may be more easily identified angiographically in the context of massive exudation, which obscures visualization of vascular lesions. The angiographic features of Coats disease include areas of nonperfusion, telangiectatic capillaries most prominent in the temporal macula, and "light bulb" aneurysms (Fig. 4).<sup>80,125</sup> Additional common angiographic findings include vascular leakage, tortuosity, and blockage from overlying exudate.<sup>68,118,125</sup> Wide-field angiography (Figs. 8 and 9) and RetCam imaging (Clarity Medical Systems Inc., Pleasanton, CA) may improve detection of isolated peripheral Coats disease or help with early detection of disease extent. Indocyanine green angiography has rarely been reported in Coats disease,<sup>20</sup> but may assist in cases where underlying choroidal pathology, such as tumor or choroidal neovascularization, are suspected.



**Fig. 5** – Submacular exudate and serous retinal detachment in Coats disease. Stage 3 disease involving the macula with diffuse vascular tortuosity, characteristic temporal aneurysms, and dense submacular yellow-white exudate with overlying hemorrhage.



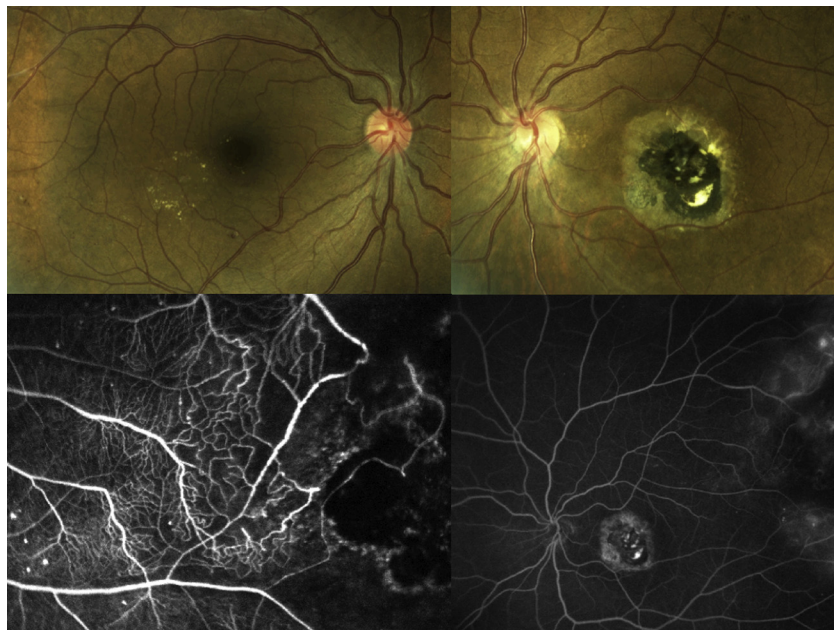
**Fig. 6 – Epiretinal gliosis and chorioretinal scar following cryotherapy to vascular abnormalities in Coats disease.**

#### 3.4. Optical coherence tomography

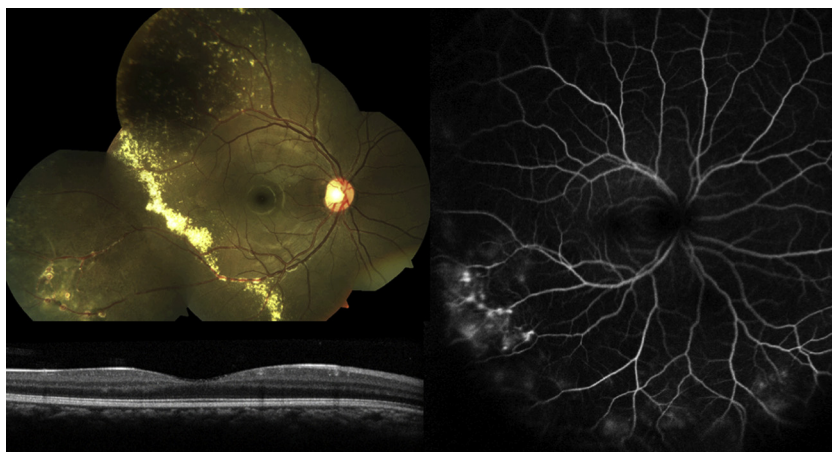Optical coherence tomography (OCT) is useful in identifying subtle macular edema or cystic changes and to monitor response to treatment.<sup>57,65</sup> OCT's role in Coats disease parallels those for other retinal disorders in the era of anti-VEGF therapy. The recent development of intraoperative OCT allows high-resolution imaging during an examination under anesthesia.<sup>57</sup> Identification of subretinal fluid, exudate, and hemorrhage, as well as assessment of the integrity of specific retinal layers, may be visible with OCT in patients with Coats disease.

#### 3.5. Computed tomography and magnetic resonance imaging

Radiologic imaging of the globe and orbit may be obtained with computed tomography (CT)<sup>51,78</sup> and magnetic resonance imaging (MRI)<sup>46,53,78</sup> (Fig. 10). CT and MRI are particularly useful in differentiating cases of advanced Coats disease from malignant lesions producing a similar clinical picture.<sup>105</sup> CT with and without contrast demonstrates calcifications that are common in retinoblastoma but not in Coats, vascularity, presence of subretinal lesions, and extraocular orbital or



**Fig. 7 – Macular fibrosis in Coats disease. Right eye of an adult female demonstrating findings consistent with type 1 idiopathic macular telangiectasia, with microaneurysms and exudate in the temporal macula (upper left); left eye demonstrating a large chorioretinal scar with subretinal fibrosis, the so-called “macular fibrosis” due to previous exudate and choroidal neovascularization (upper right); fluorescein angiography of the left eye reveals telangiectatic vessels and aneurysmal dilations typical of Coats disease (lower left); wide-field fluorescein angiography demonstrates areas of temporal retinal capillary non-perfusion, leakage from aneurysmal, telangiectatic capillaries, and staining of the central macular scar (bottom right).**



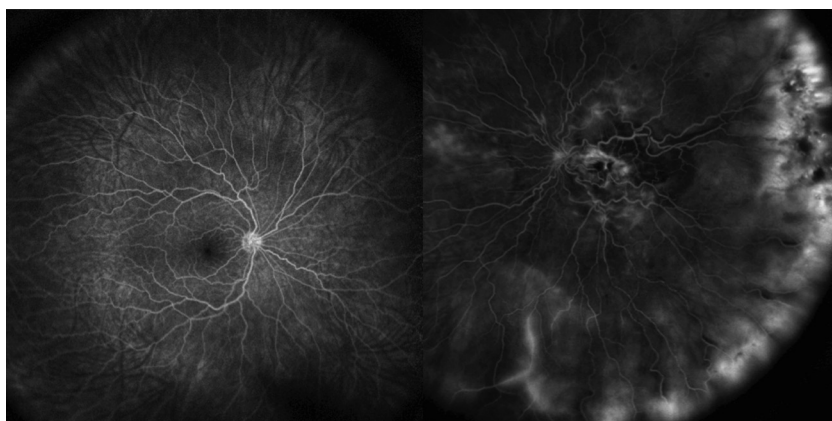
**Fig. 8 – Fundus photography and wide-field fluorescein angiogram of a patient with Coats disease. Composite fundus photo with diffuse peripheral exudate and inferotemporal vascular tortuosity (upper left); wide-field fluorescein angiogram demonstrating “light-bulb” aneurysms and additional inferior regions of peripheral vascular leakage (right); optical coherence tomography demonstrating normal foveal contour.**

intracranial lesions such as metastases from an underlying malignancy.<sup>51,52</sup> In addition, globe volumes may be significantly lower than for normal eyes or retinoblastoma in Coats disease.<sup>39,48</sup> MRIs demonstrate hyperintense T1- and T2-weighted signal converging on the optic nerve head corresponding to an exudative retinal detachment.<sup>34,53</sup> This is in contrast to retinoblastoma, which is relatively hypointense on T2-weighted images (Fig. 10).<sup>32,34</sup> After contrast administration, retinoblastoma reveals mass-like enhancement, in contrast to advanced Coats disease, which demonstrates linear enhancement convergent on the optic nerve head corresponding to detached retina.<sup>32,34,77</sup> As there are several additional differentiating features between retinoblastoma and Coats disease visible with MRI and there is no ionizing radiation exposure, this imaging modality has been advocated as particularly efficacious.<sup>32,34,77</sup> A diffuse retinal detachment contiguous with the optic nerve, a T1 MRI signal that is isodense with extraocular muscle and hyperintense signal on T2 MRI is consistent with Coats disease.

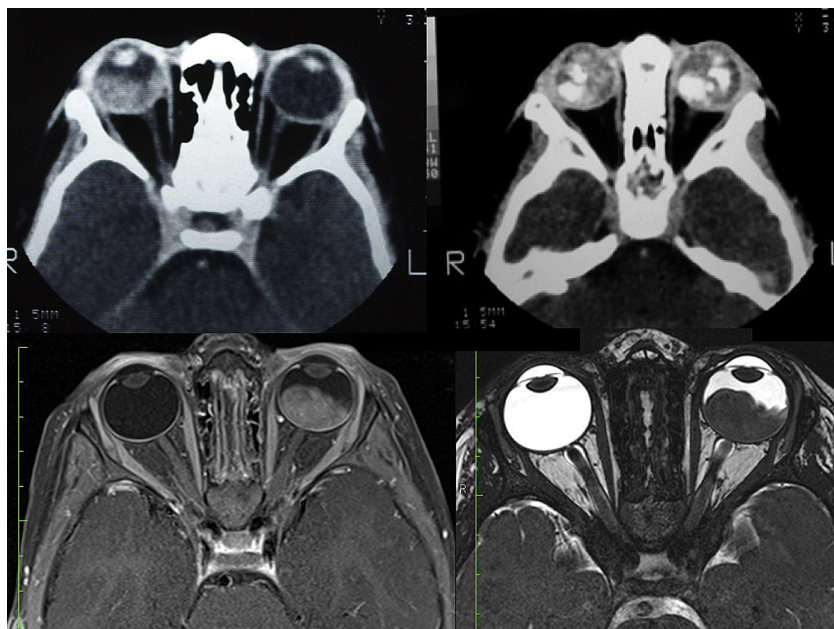
### 3.6. Variants and differential diagnosis

#### 3.6.1. Tumors

**3.6.1.1. Retinoblastoma.** Coats disease is only one of a spectrum of disorders causing childhood leukocoria.<sup>59,113</sup> Anticipation of atypical Coats-like presentations of ocular malignancies is essential to avoid rare but potentially severe clinical consequences.<sup>51,71,105,107,120</sup> Because both advanced Coats disease and retinoblastoma may present with the triad of retinal detachment, apparent subretinal mass, and dilated vasculature,<sup>61,71</sup> surgical procedures could have a potentially fatal outcome if an unsuspected retinoblastoma seeds adjacent orbital tissues. Although differentiating features between Coats disease and retinoblastoma may be obvious from clinical examination in early stages of disease, even the most experienced observer may find it impossible to differentiate these entities based on ophthalmoscopic findings alone for diffuse or advanced disease, particularly in the context of a poor view of the posterior segment.



**Fig. 9 – Bilateral wide-field fluorescein angiogram of a patient with Coats disease. The right eye is unaffected, demonstrating normal vascular morphology; the left eye includes stage 3 disease with diffuse vascular tortuosity, macular leakage, blockage from dense submacular exudate, and exudative retinal detachment with diffuse peripheral vascular leakage.**



**Fig. 10 – Diagnostic imaging in Coats disease and retinoblastoma. Axial contrast enhanced computed tomography of a patient with Coats disease reveals a retinal detachment in the right eye which is isodense with extraocular muscle and lacks calcification (upper left); axial contrast enhanced computed tomography in a patient with bilateral retinoblastoma reveals intraocular masses with abundant calcification (upper right); axial T1 MRI in a patient with left exophytic retinoblastoma demonstrates an intraocular mass, (lower left); axial T2 MRI of the same patient with left exophytic retinoblastoma revealing mass-like hypointense signal (lower right).**

Misdiagnosing Coats disease as retinoblastoma may result in the enucleation of a potentially salvageable eye and is the most common reason for enucleation with the incorrect diagnosis of retinoblastoma.<sup>51,61</sup> Conversely, mistaking a case of retinoblastoma for Coats disease delays the appropriate therapeutic intervention and increases the possibility of extraocular tumor spread, especially if intraocular surgery is performed. Because it is exceedingly rare to salvage useful vision in a child with advanced Coats disease, it is appropriate to enucleate any eye in which retinoblastoma cannot be excluded.

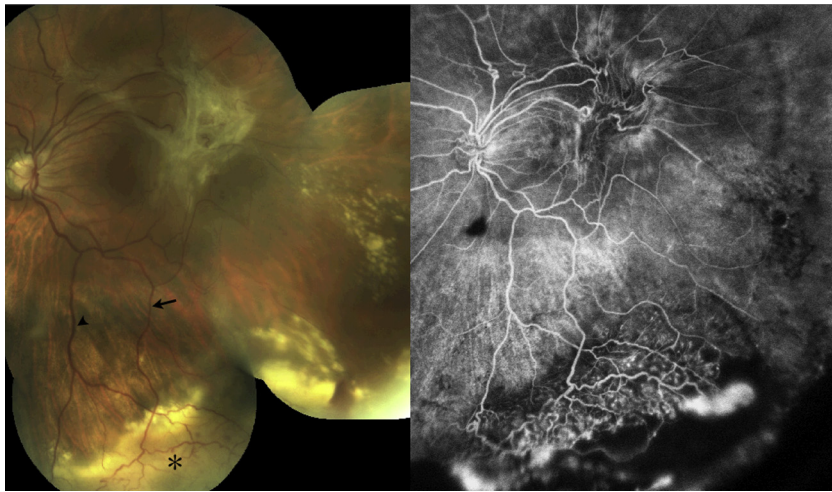
**3.6.1.2. Hamartomas and vasoproliferative tumors.** Additional lesions producing focal retinal angiomatous lesions have been recognized as distinct clinical entities. Hamartomas including capillary hemangiomas<sup>98,104,110,111,112</sup> and cavernous hemangiomas<sup>40,83,90</sup> have been reported to simulate a Coats-like retinopathy. Helpful differentiating clinical features are the lack of prominent exudate and characteristic morphology in the majority of cases. Cavernous and capillary hemangiomas occur more commonly in a peripapillary location than Coats disease. Capillary hemangiomas contain prominent feeder vessels and have a characteristic focal angiographic appearance when endophytic. Capillary hemangiomas, or hemangioblastomas occur primarily as part of Von Hippel-Lindau syndrome, the dominantly inherited phakomatosis. Exophytic lesions may be more difficult to differentiate from Coats disease, especially if accompanied by exudate.

Retinal vasoproliferative tumor, or “acquired retinal capillary hemangioma,”<sup>72,103</sup> has many of the same characteristic

features of Coats disease, including unilaterality, temporal periphery location, prominent exudate, and serous retinal detachment. The presence of specific feeder and draining vessels, a vascular mass, and vitreoretinal interface abnormality<sup>6,25,103</sup> such as preretinal fibrosis are possible differentiating features (Fig. 11). Unlike the hemangiomas present in Von Hippel-Lindau, primary vasoproliferative tumors have no or minimally dilated feeder vessels and demonstrate frequent exudate, serous retinal detachment, and far-peripheral, inferotemporal location.<sup>103</sup> There is considerable overlap between adult Coats disease and secondary vasoproliferative tumors.<sup>17,56,58,72,103</sup> Like Coats disease, vasoproliferative tumors are associated with, and are presumably secondary to, underlying retinal pathology such as retinitis pigmentosa<sup>82,103</sup> and intermediate uveitis.<sup>103,106</sup> The treatment of vasoproliferative tumor is nearly identical to Coats disease, but has additionally been successfully managed with photodynamic therapy<sup>11</sup> and radioactive plaque brachytherapy.<sup>3,22,87</sup>

**3.6.1.3. Additional tumors.** Several additional atypical presentations of retinal or choroidal tumors have been associated with exudate or serous retinal detachment and confused with Coats disease.<sup>105</sup> For this reason, it is important to maintain a differential diagnosis for all instances of Coats-like retinopathy. Choroidal melanoma does not typically present with prominent exudate and demonstrates a characteristic pigmented choroidal mass in most cases; amelanotic melanomas with a serous retinal detachment and exudative component may simulate Coats disease, however.<sup>103</sup>





**Fig. 11 – Retinal vasoproliferative tumor. Fundus photography of the left eye of an adult with a dense epimacular fibrous membrane and an inferotemporal vascular mass (asterisk) with subretinal exudate and hemorrhage (left); there is a specific feeding arteriole (arrow) and draining venule (arrowhead) that are minimally dilated, features which, along with epimacular fibrosis make the diagnosis of vasoproliferative tumor more likely than Coats disease; wide-field fluorescein angiography reveals the inferotemporal vascular lesion with telangiectatic vessels, leakage, and epiretinal neovascularization (right).**

### 3.6.2. Inherited and congenital vitreoretinal disorders

**3.6.2.1. Retinitis pigmentosa.** A Coats-like retinopathy is associated with retinitis pigmentosa, occurring in up to 4% of patients.<sup>66,94</sup> This exudative presentation of retinitis pigmentosa is frequently bilateral<sup>66</sup> and does not appear to be a feature of X-linked retinitis pigmentosa.<sup>66</sup> As noted earlier, the identified genetic features of this condition appear to differ from classic Coats disease.<sup>23,26</sup> The disorder typically presents in a patient with a long-standing history of retinitis pigmentosa. Treatment is identical to the treatment for classic Coats disease and involves ablation of abnormal telangiectatic vessels.

**3.6.2.2. Norrie disease.** Norrie disease is a rare congenital retinal dysgenesis syndrome with X-linked recessive inheritance, sensorineural hearing loss, and cognitive impairment.<sup>4,114,131–133</sup> Patients are typically blind from birth and have massive bilateral retinal disorganization with a “pseudoglioma” appearance to the retina. Progressive hearing loss typically develops later in childhood.<sup>114</sup> Norrie disease has been linked to several mutations in the Norrie disease protein, which has also been found in some cases of familial exudative retinopathy.<sup>10</sup> Family history, bilaterality, syndromic features, and the presence of the typical gliotic appearing retinal mass or “pseudoglioma” help differentiate this disorder from childhood Coats disease.

**3.6.2.3. Persistent fetal vasculature.** Persistent fetal vasculature, formerly known as persistent hyperplastic primary vitreous, is an additional cause of childhood leukocoria that may be confused with Coats disease.<sup>53,78,105</sup> Persistent fetal vasculature is, however, typically nonprogressive and lacks the exudative features present in Coats disease. Anterior segment findings, particularly cataract, occur early and are a common feature of the disorder, unlike Coats disease. Like

Coats, a smaller affected eye may be evident with radiologic studies.<sup>78</sup> Unlike Coats, persistent fetal vasculature with significant vitreoretinal traction and a central vascular stalk through the central hyaloidal canal may be present on both clinical exam and B-scan ultrasonography.

**3.6.2.4. Familial exudative vitreoretinopathy.** Familial exudative vitreoretinopathy (FEVR) is another hereditary vitreoretinal disorder that may present with childhood leukocoria, vision loss, and exudative retinal detachment.<sup>24,84</sup> Unlike Coats disease, the disorder is typically bilateral, demonstrates no sex predilection, and frequently has vitreoretinal membranes and tractional retinal detachments.<sup>91</sup> FEVR may demonstrate autosomal dominant or X-linked recessive inheritance. Autosomal dominant FEVR has been linked to genes on chromosome 11,<sup>29,126</sup> which encode proteins involved in the Wnt signaling pathway. X-linked FEVR has been linked to missense mutations in the Norrie disease protein.<sup>10</sup>

### 3.6.3. Idiopathic retinal vascular diseases and inflammation

**3.6.3.1. Uveitis and retinal vasculitis.** Disorders with posterior uveitis and retinal vasculitis that cause retinal capillary non-perfusion, aneurysmal dilations, and exudation may simulate Coats disease.<sup>47</sup> In fact, intermediate uveitis may lead to retinal vasoproliferative tumor that exhibits a Coats-like retinopathy.<sup>103</sup> Eale disease, an idiopathic peripheral retinal vasculitis may be confused with Coats disease, but typically occurs bilaterally, and exudation is uncommon.<sup>5,35,119</sup> In addition, any posterior uveitic condition producing serous retinal detachment, such as scleritis with an exudative component, may simulate Coats disease.<sup>7</sup>

**3.6.3.2. Macular telangiectasia.** Type 1 idiopathic macular telangiectasia, as previously discussed, is usually considered as part of the clinical spectrum of Coats disease. Unilateral

aneurysmal retinal vascular dilations in the temporal periphery of a nondiabetic patient define the condition (Fig. 2). With the advent of wide-field fluorescein angiography, peripheral lesions similar to Coats disease have been identified in some cases, further supporting the notion that type 1 idiopathic macular telangiectasia is a precursor to or a milder form of Coats disease. Type 2 idiopathic macular telangiectasia is a distinct clinical entity involving bilateral telangiectatic retinal capillaries and degenerative cystic perifoveal spaces.<sup>41,135</sup> The disorder may produce yellow crystalline deposits in the macula and a gray sheen in the temporal perifoveal region, but significant exudate and subretinal fluid are not features. Type 3 idiopathic macular telangiectasia is a rare clinical diagnosis demonstrating an occlusive microvascular retinopathy,<sup>41,135</sup> but lacks most features of Coats disease and may be secondary to previous retinal vascular disease such as retinal vein occlusion.

#### 3.6.4. Other retinal vascular disorders producing retinal vascular dilations and exudation

Diabetic retinopathy should rarely, if ever, be confused with Coats disease because of the medical history, typical systemic features, bilateral nature, typical microaneurysms, presence of epiretinal neovascularization, and vitreoretinal traction when peripheral retinal detachment is present. Nevertheless asymmetric and highly exudative presentations of diabetic retinopathy may simulate a Coats-like retinopathy. Central or branch retinal vein occlusion, particularly when highly exudative, may simulate Coats disease.<sup>101</sup> Typical sudden onset in an adult with characteristic retinal nerve fiber layer hemorrhages make clinical differentiation less challenging. Retinal macroaneurysm has a characteristic appearance, an association with hypertension and other retinal vascular disorders, and typically exhibits less diffuse exudation.

## 4. Current clinical management

### 4.1. Vascular ablation

#### 4.1.1. Historical considerations

Early treatment for Coats disease revolved around the hypothesis that the disorder arose from an underlying infectious or inflammatory etiology.<sup>60,127</sup> Various attempts at treatment with antibiotics and anti-inflammatory agents had no apparent effect. The first treatment successes were vascular ablation with transscleral diathermy<sup>50</sup> or radiation therapy.<sup>54,60</sup> Either ruby or xenon arc photocoagulation<sup>93,117</sup> then became the treatment of choice for most. Subsequent therapies have built upon the basic clinical goal of destroying abnormal vasculature and aneurysmal dilations, leading to the reduction in vascular leakage and exudation.

#### 4.1.2. Cryotherapy

Telangiectatic vessels in the far peripheral retina in the setting of total exudative retinal detachment may preclude adequate laser photocoagulation; therefore, cryotherapy has been traditionally used in this setting.<sup>51</sup> Cryotherapy may be used under indirect ophthalmoscopy and is deployed until a white freeze reaction is observed. Treatment of all abnormal areas

and a margin of normal tissue are performed three times within the same session (triple freeze/thaw therapy). As with photocoagulation, a therapeutic interval of 4 to 6 weeks is used to gauge adequate treatment response, and re-treatment provided if necessary.<sup>51</sup> There is some evidence that cryotherapy increases epiretinal membrane formation and retinal traction.<sup>43</sup> Therefore we prefer to avoid cryotherapy in Coats disease, because adequate ablation of retinal telangiectasis can be performed with laser photocoagulation, even in the setting of subretinal fluid, as described. Nevertheless, cryotherapy is a known effective method of achieving resolution of exudate, telangiectasis, and vascular ablation in Coats retinopathy.

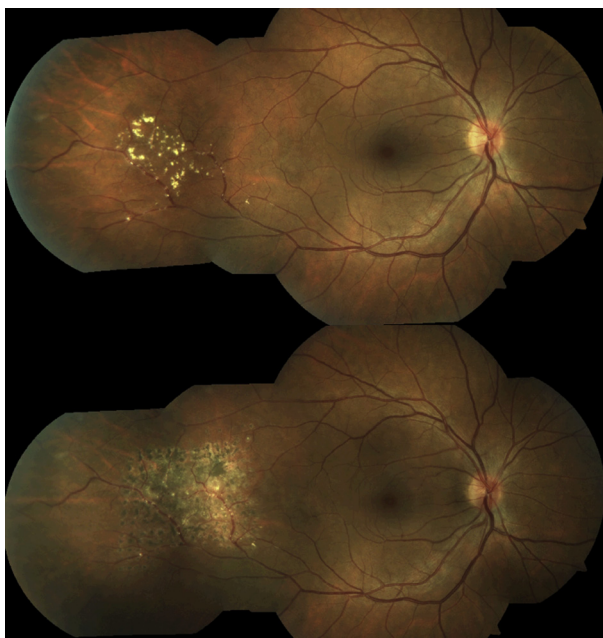
#### 4.1.3. Thermal laser photocoagulation

Photocoagulation early in Coats disease, first described by Meyer-Schwickerath, has historically been the most efficacious treatment.<sup>38,93,117</sup> Laser photocoagulation converts monochromatic, coherent light energy to heat energy. Consequently, the temperature of the absorbent tissue rises, resulting in protein denaturation and tissue coagulation.<sup>81</sup> The tissue absorbing the light energy is the chromophore, and its absorption capacity is determined by its absorption spectrum in relation to the incident laser wavelength. Normal retina is a poor chromophore because of its transparency. Retinopexy for retinal breaks utilizes the absorptive properties of the retinal pigment epithelium and requires contact between the pigment epithelium and the overlying retina for development of a chorioretinal adhesion. In contrast, the goal in Coats disease is to obliterate abnormal vasculature and hyperpermeable aneurysmal dilations. Therefore, the absorptive property of hemoglobin to 532 nm (green) laser light is adequate for vascular absorption of laser energy, and this wavelength can be utilized for direct photocoagulation of vascular anomalies even in the presence of subretinal fluid.<sup>88</sup> Infrared laser wavelengths have inadequate absorption spectra for intravascular chromophores. Photocoagulation arrests the exudative process by destroying defective retinal blood vessels, particularly telangiectasias and aneurysms (Fig. 12). The effectiveness of the treatment may decrease when more than two quadrants of the retina exhibit vascular abnormalities.<sup>88,107</sup> Close follow-up is required following ablative therapy, as late recurrences may require additional treatment.<sup>88,92,107</sup>

### 4.2. Anti-VEGF therapy

#### 4.2.1. Role of VEGF in Coats disease

A number of recent reports address the role of vascular endothelial growth factor (VEGF) in Coats disease<sup>55,122</sup> and the use of intravitreal anti-VEGF compounds as an adjunct<sup>15,44,64,67,95,121,122,128,130</sup> or single therapy.<sup>2,14,36,75</sup> VEGF levels are markedly elevated in Coats disease,<sup>55,122</sup> and intravitreal bevacizumab (Avastin, Genentech, South San Francisco, CA) is highly effective in decreasing edema and exudate and may even induce resolution of total retinal detachment after a single administration.<sup>136</sup> Sun et al<sup>122</sup> and Kaul et al<sup>64</sup> demonstrated clinical improvement and decreased VEGF levels after pegaptanib therapy. Ramasubramanian et al found an increase in fibrosis and vitreoretinal traction



**Fig. 12 – Response to laser photocoagulation in Coats disease. Before treatment, exudate is located in the temporal mid-periphery overlying telangiectatic retinal capillaries (upper image); 6 weeks following treatment, pigmented laser scars are visible and most exudate has resolved (lower image).**

following bevacizumab for Coats disease; as all patients received cryotherapy, the eyes included were skewed toward more severe disease, however, and there was no visual data presented in this small series. We have noticed subretinal fibrotic bands in published images that were not specifically commented on, but these did not appear to involve the macula, occurring predominantly within peripheral areas of localized retinal detachment. Improvement in exudate and subretinal fluid occurred in all cases in Ramasubramanian et al's series, with no retinal breaks or progression to more severe stage of disease. The overwhelming weight of evidence, therefore, supports the use of anti-VEGF therapy for Coats disease with retinal edema or exudate involving the macula or when adequate ablative therapy cannot be used. A summary of the published experience to date with intravitreal bevacizumab in Coats disease is presented in Table 1.

Further experience will reveal how the visual and anatomic prognosis of severe Coats disease may change in the era of anti-VEGF therapy. We have had favorable visual and anatomic results at greater than 2 years of follow-up in our unpublished series of patients receiving a single treatment of intravitreal bevacizumab, 1.25 mg/0.05 mL, followed by argon laser photocoagulation in a single session. Two patients experienced resolution of total retinal detachment following bevacizumab therapy alone. Small sample size and inability to objectively measure vision in most patients at presentation make identification of a statistically significant visual benefit difficult; mean visual outcome in the bevacizumab group appears improved compared to those receiving ablative therapy alone, however. We currently recommend initial

treatment consisting of a single intravitreal anti-VEGF treatment for any significant macular edema, exudate, or serous retinal detachment, with ablative therapy with argon laser photocoagulation either concomitant with anti-VEGF administration or following resolution of exudate and edema.

#### 4.3. Combined treatment and vitreoretinal surgery

##### 4.3.1. Vascular ablation combined with anti-VEGF or corticosteroid

Much of the current experience with anti-VEGF therapy combines vascular ablation, primarily laser photocoagulation, or cryotherapy. Therefore, the true efficacy of anti-VEGF therapy as primary therapy for Coats disease remains unknown, although cases treated with bevacizumab alone do demonstrate a favorable clinical response. We have observed dramatic improvement in macular edema and exudate in patients treated with a single intravitreal bevacizumab administration when combined with laser photocoagulation (Fig. 13) and for persistent macular edema following previous ablative therapy (Fig. 14). Intravitreal corticosteroids such as triamcinolone acetate have met with some degree of success<sup>8,15,89</sup> as an adjuvant to ablative therapy for decreasing subretinal fluid and exudate. One series of cases experienced total exudative retinal detachment resolution following intravitreal triamcinolone.<sup>42</sup> In light of recent success and the improved side-effect profile of anti-VEGF therapy, however, corticosteroids may be less indicated because of the risk of glucocorticoid-induced intraocular pressure elevation, endophthalmitis, and cataract.

##### 4.3.2. Vitreoretinal surgery for refractory cases

In advanced Coats disease, photocoagulation and/or cryotherapy may not halt progression.<sup>51,85,88,99</sup> The extensive subretinal exudate may prevent the cryotherapy "ice ball" from contacting the abnormal vessels located on the elevated retina. Areas of telangiectasia inaccessible to laser may need retreatment after subretinal fluid resolution. These cases may require drainage of subretinal exudative fluid to assist in restoring the apposition between the neural retina and retinal pigment epithelium,<sup>51,85</sup> particularly when fibrosis prevents complete retinal reattachment. These surgical procedures may facilitate treatment of abnormal vessels by photocoagulation or cryotherapy, thereby inhibiting further accumulation of exudates or at least preventing progression to phthisis bulbi.<sup>38,107</sup>

Vitrectomy should be considered as a last resort for intractable total retinal detachments, a situation less often encountered in the era of anti-VEGF therapy. Surgical intervention may be required in cases with significant epiretinal traction from preretinal membranes or proliferative vitreoretinopathy.<sup>63,85,108</sup> Eyes with Coats disease may have an abnormal transretinal pressure gradient, because the retinal pigment epithelium capacity to maintain a fluid-free subretinal space may be overwhelmed by the exudative process. Therefore, internal drainage retinotomies should be avoided. Retinal breaks may lead to a persistent total exudative/rhegmatogenous retinal detachment as a result of the underlying RPE deficiency. Transscleral subretinal fluid drainage may then be required. One small case series describes successful

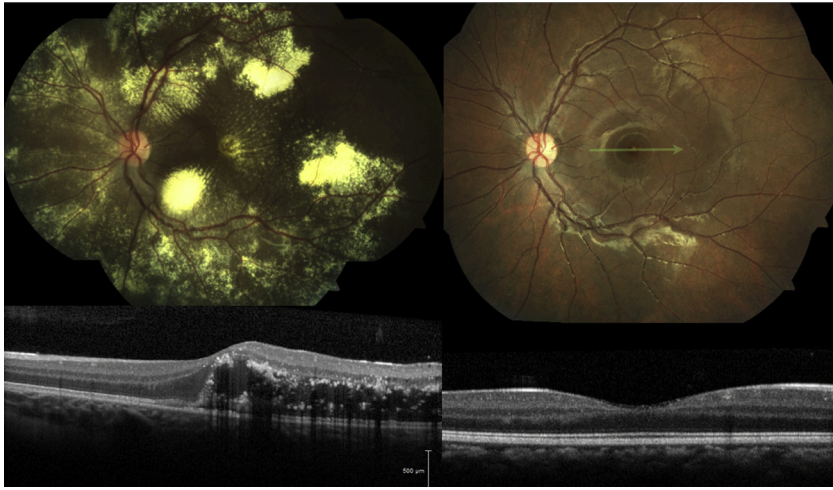
**Table 1 – Summary of current experience with intravitreal bevacizumab in Coats disease**

| Investigator (first author)   | Year | n              | Follow-up (months) | Outcome measures   | Additional treatment <sup>a</sup>  | Comments   |
|-------------------------------|------|----------------|--------------------|--|--|--|
| Cakir <sup>15</sup>           | 2008 | 1              | 3                  | subretinal fluid, leakage, vision                                  | triamcinolone, Ar laser  | superior RD resolved, subretinal bands extramacular, improved vision   |
| Venkatesh <sup>128</sup>      | 2008 | 2              | 12                 | leakage, vision  | Ar laser 6 weeks following IVB   | female patients, resolved macular edema, visual improvement in 50%   |
| Alvarez-Rivera <sup>2</sup>   | 2008 | 1              | 1                  | Vision, subretinal fluid   | none   | female patient, RD and exudate improved, vision stable   |
| Stergiou                      | 2009 | 1              | 4                  | Macular edema, exudate, vision                                     | Single Ar laser at presentation  | 3 IVB over 4 months, exudate improved, vision 20/1000-20/60  |
| Cackett                       | 2010 | 1              | 12                 | subretinal fluid, exudate, vision                                  | Ar laser subsequent to IVB   | improved vision, decrease in subretinal fluid and exudate following IVB alone  |
| Lin                           | 2010 | 3              | 12                 | Macular edema, subretinal fluid, leakage, exudate, vision          | Ar laser or Cryo following IVB in 2 cases, IVB after refractory to Laser and Triamcinolone in one case | macular edema improved in previous refractory case, exudate and vision improved in all cases, vision improved in all cases, RD improved, 3 monthly IVB in all cases                      |
| Kaul <sup>64</sup>            | 2010 | 2 <sup>b</sup> | mean = 4           | Subretinal fluid, vision   | External drainage, Ar laser, SF <sup>6</sup>   | RD resolved, decreased macular edema   |
| Goel <sup>44</sup>            | 2011 | 3              | 9                  | macular edema, exudate, vision                                     | Ar laser 3 weeks following IVB   | Adult patients, all with improved vision   |
| Wang <sup>130</sup>           | 2011 | 3              | mean = 14          | vision, exudate, macular edema, telangiectasias                    | Ar laser   | 2 monthly injections, improvement in exudate, macular edema, telangiectasia, and vision  |
| Zhao <sup>136</sup>           | 2011 | 1              | 6                  | subretinal fluid, vision   | none   | IVB alone, resolution of total RD, improved vision   |
| Ramasubramanian <sup>95</sup> | 2012 | 8              | mean = 8.5         | subretinal fluid, exudate, telangiectasias, vitreoretinal fibrosis | Cryo (100%), Laser (50%)   | range 1–4 injections, 50% vitreoretinal fibrosis, $\frac{3}{8}$ TRD, 100% resolution subretinal fluid, 100% improvement in telangiectasias, 75% resolution of exudate, no retinal breaks |
| Beselga <sup>9</sup>          | 2012 | 1              | 12                 | vision, macular edema, exudate                                     | PDT, Ar laser  | Stable subretinal fluid, progressed to macular fibrosis  |
| Sigler <sup>c</sup>           | 2012 | 14             | mean = 21          | vision, RD, exudate, macular edema                                 | Ar laser   | 1 case with resolution of total RD, improvement in exudate and macular edema in all cases  |
| Sigler <sup>c</sup>           | 2012 | 6              | mean = 19          | vision, RD, exudate, macular edema                                 | none   | 2 patients with resolution of total RD, improvement in macular edema and exudate in all cases  |

<sup>a</sup> Ar, argon laser photocoagulation; IVB, intravitreal bevacizumab; RD, exudative retinal detachment.

<sup>b</sup> One case with pegaptanib not included.

<sup>c</sup> Current authors' experience, previously unpublished data.

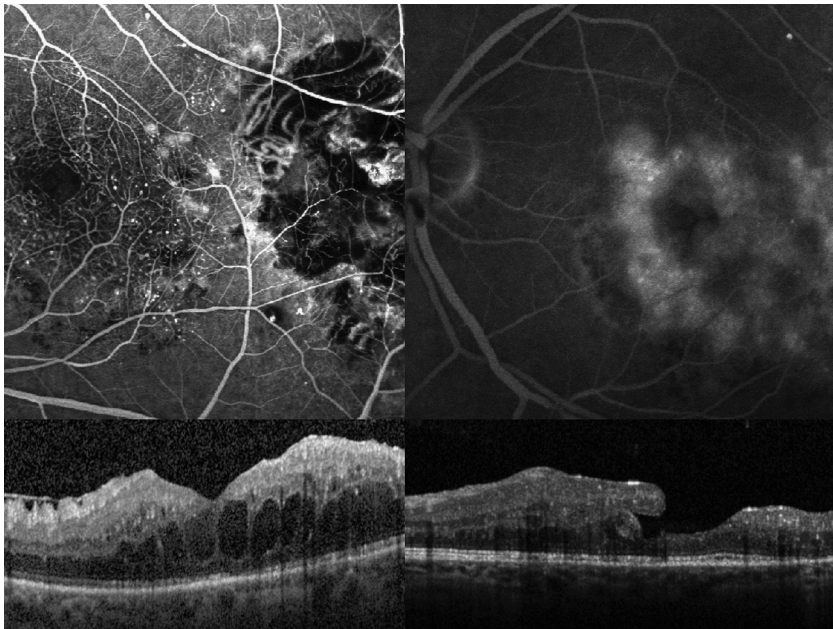


**Fig. 13** – Response to combined anti-vascular endothelial growth factor compounds and laser photocoagulation in Coats disease. Pretreatment there is diffuse exudate in all four retinal quadrants as well as serous retinal detachment (*upper left*); 6 months following a single intravitreal bevacizumab treatment and focal laser photocoagulation to temporal telangiectatic vessels, exudate has completely resolved (*upper right image*); green tracing denotes raster line for optical coherence tomography demonstrating subfoveal exudate and macular edema (*lower left*); following treatment, edema and exudate has completely resolved (*lower right*).

anatomic and visual outcomes following vitrectomy with internal drainage of subretinal fluid and silicone oil tamponade.<sup>86</sup>

For severe Coats disease (stage 4 and 5 disease), our findings,<sup>51</sup> similar to those of previous reports,<sup>1,107</sup> suggest that subretinal drainage combined with vitreous infusion and ablation of abnormal vasculature can preserve the globe. As

a result, patients with Coats can experience normal orbital growth and not suffer the cosmetic and psychological side effects associated with enucleation. Unfortunately, few patients appear to retain useful vision in advanced disease.<sup>13,51,107</sup> In fact, a majority of patients in the largest series of Coats disease to date had visual outcomes of 20/200 or worse.<sup>107</sup> This may relate to the massive photoreceptor



**Fig. 14** – Response of persistent macular edema following cryotherapy to anti-VEGF therapy in Coats disease. Fluorescein angiography demonstrates chorioretinal scarring in the area of previous cryotherapy temporal to the macula, but persistent aneurysmal dilations surrounding the fovea (*upper left*); recirculation phase angiogram reveals diffuse macular leakage (*upper right*); optical coherence tomography reveals diffuse cystic macular edema (*lower left*); 1 month following treatment with intravitreal bevacizumab, edema has resolved (*lower right*).

degeneration from the effects of subretinal exudation in advanced disease.<sup>51</sup>

#### 4.3.3. Clinical approach to Coats disease management

The broad spectrum of disease phenotype and clinical behavior present in Coats disease makes clinical diagnosis and management challenging. Nevertheless, prompt recognition and initiation of management may lead to an improved clinical outcome. The classification system of Shields et al provides a useful approach to clinical severity with prognostic significance. We currently recommend treatment based on patient factors and severity of disease. Pediatric patients should have careful examination under anesthesia that addresses the differential diagnosis outlined above prior to treatment initiation. Baseline fundus photography, wide-field angiography, and intraoperative OCT should be performed if available. Eyes with peripheral telangiectasis without exudate or retinal detachment (Shields stage 1) may be observed; we prefer to treat initially with laser ablation, however, because of its minimal risk and the potential to prevent exudates. For eyes with significant exudate, subretinal, or intraretinal fluid without glaucoma (stages 2 and 3), we administer intravitreal anti-VEGF agents. Thermal laser ablation should be initiated even in the presence of subretinal exudate or fluid, as described. We prefer to avoid cryotherapy because of its tissue-destructive and proliferative vitreoretinopathy-inducing potential. We recommend close follow-up based on the duration of anti-VEGF intravitreal activity (i.e., at least monthly) until disease stabilization. For adult patients with a significant exudative process, intravitreal anti-VEGF agents combined with laser ablation may be performed as an outpatient, with monthly follow-up until disease stabilization. Type I idiopathic macular telangiectasia and those patients with mild disease with extra-foveal abnormal vasculature only and minimal exudate may be treated with laser vascular ablation alone. Patients with foveal aneurysmal dilations and evidence of macular edema should be treated with anti-VEGF agents alone. Patients with severe (stage 4) disease with glaucoma may require surgical intervention. We currently use 25-gauge pars plana vitrectomy and external drainage of subretinal fluid, when possible, prior to vascular ablation with endolaser photocoagulation for select cases with stage 4 disease. End-stage Coats disease (stage 5) with no light perception and a comfortable, cosmetically acceptable globe may be observed without treatment, whereas persistently painful, blind eyes should be considered for enucleation.

## 5. Conclusion

Despite significant advancement in the scientific understanding of Coats disease and its clinical spectrum, the underlying etiology remains obscure, with both primary and secondary forms recognized. With the development of anti-VEGF therapy, vitreoretinal specialists have a new, effective adjunct for the clinical management of exudate, macular edema, and serous retinal detachment. Further experience

will determine if the long-term visual prognosis, historically poor, will improve.

## 6. Method of literature search

A literature search including Medline via the PubMed platform, Scopus, and Embase was performed for the keywords *Coats disease*, *Leber multiple miliary aneurysms*, and *type 1 idiopathic macular telangiectasia*. Each outline subheading was developed after literature review and was used as an additional keyword. The search was expanded as necessary using the Related Articles function within PubMed. Only high quality, peer-reviewed articles and original descriptions were considered. Case reports were only referenced if they appeared to provide new information about a previously poorly characterized aspect of disease. International articles published in different language were included, particularly for the original descriptions present in the introduction, and English translations were used for our review.

## 7. Disclosure

The authors report no financial or conflict of interest in any concept or product reported in the present review. The research efforts of the authors are supported in part by an unrestricted grant from Research to Prevent Blindness, Inc., New York, NY, and The Ayers Foundation, Parson, TN.

## REFERENCES

1. Adam RS, Kertes PJ, Lam WC. Observations on the management of coats' disease: less is more. *Br J Ophthalmol*. 2007;91:303–6
2. Alvarez-Rivera LG, Abraham-Marin ML, Flores-Orta HJ, et al. [Coat's disease treated with bevacizumab (Avastin)]. *Arch Soc Esp Oftalmol*. 2008;83:329–31
3. Anastassiou G, Bornfeld N, Schueler AO, et al. Ruthenium-106 plaque brachytherapy for symptomatic vasoproliferative tumours of the retina. *Br J Ophthalmol*. 2006;90:447–50
4. Andersen SR, Warburg M. Norrie's disease: congenital bilateral pseudotumor of the retina with recessive x-chromosomal inheritance; preliminary report. *Arch Ophthalmol*. 1961;66:614–8
5. Atmaca LS, Batioglu F, Atmaca Sonmez P. A long-term follow-up of Eales' disease. *Ocul Immunol Inflamm*. 2002;10:213–21
6. Baines PS, Hiscott PS, McLeod D. Posterior non-vascularized proliferative extraretinopathy and peripheral nodular retinal telangiectasis. *Trans Ophthalmol Soc UK*. 1982; 102(Pt 4):487–91
7. Benson WE, Shields JA, Tasman W, et al. Posterior scleritis. A cause of diagnostic confusion. *Arch Ophthalmol*. 1979;97:1482–6
8. Bergstrom CS, Hubbard GB 3rd. Combination intravitreal triamcinolone injection and cryotherapy for exudative retinal detachments in severe coats disease. *Retina*. 2008;28:S33–7
9. Beselga D, Campos A, Mendes S, et al. Refractory Coats' disease of adult onset. *Case Report Ophthalmol*. 2012;3:118–22

10. Black GC, Perveen R, Bonshek R, et al. Coats' disease of the retina (unilateral retinal telangiectasis) caused by somatic mutation in the NDP gene: a role for Norrin in retinal angiogenesis. *Hum Mol Genet.* 1999;8:2031–5
11. Blasi MA, Scupola A, Tiberti AC, et al. Photodynamic therapy for vasoproliferative retinal tumors. *Retina.* 2006;26:404–9
12. Bonnet M. [Coats' syndrome]. *J Fr Ophthalmol.* 1980;3:57–66
13. Budning AS, Heon E, Gallie BL. Visual prognosis of Coats' disease. *J AAPOS.* 1998;2:356–9
14. Cackett P, Wong D, Cheung CM. Combined intravitreal bevacizumab and argon laser treatment for coats' disease. *Acta Ophthalmol.* 2010;88:e48–9
15. Kahir M, Cekic O, Yilmaz OF. Combined intravitreal bevacizumab and triamcinolone injection in a child with coats disease. *J AAPOS.* 2008;12:309–11
16. Campbell FP. Coats' disease and congenital vascular retinopathy. *Trans Am Ophthalmol Soc.* 1976;74:365–424
17. Campochiaro PA, Conway BP. Hemangiomalike masses of the retina. *Arch Ophthalmol.* 1988;106:1409–13
18. Chang MM, McLean IW, Merritt JC. Coats' disease: a study of 62 histologically confirmed cases. *J Pediatr Ophthalmol Strabismus.* 1984;21:163–8
19. Char DH. Coats' syndrome: long term follow up. *Br J Ophthalmol.* 2000;84:37–9
20. Chen C, Wen F, Jiang L, et al. A macular hole in a female adult with bilateral Coats disease. *Yan Ke Xue Bao.* 2003;19:168–70
21. Coats G. Forms of retinal diseases with massive exudation. *R Lond Ophthalmol Hosp Rep.* 1908;17:440–525
22. Cohen VM, Shields CL, Demirici H, et al. Iodine i 125 plaque radiotherapy for vasoproliferative tumors of the retina in 30 eyes. *Arch Ophthalmol.* 2008;126:1245–51
23. Cremers FP, Maugeri A, den Hollander AI, et al. The expanding roles of ABCA4 and CRB1 in inherited blindness. *Novartis Found Symp.* 2004;255:68–79, discussion 79–84, 177–8
24. Criswick VG, Schepens CL. Familial exudative vitreoretinopathy. *Am J Ophthalmol.* 1969;68:578–94
25. Damato B. Vasoproliferative retinal tumour. *Br J Ophthalmol.* 2006;90:399–400
26. den Hollander AI, Davis J, van der Velde-Visser SD, et al. CRB1 mutation spectrum in inherited retinal dystrophies. *Hum Mutat.* 2004;24:355–69
27. Deutsch TA, Rabb MF, Jampol LM. Spontaneous regression of retinal lesions in Coats' disease. *Can J Ophthalmol.* 1982;17:169–72
28. Dow DS. Coats' disease: occurrence in a four-month-old infant. *South Med J.* 1973;66:836–8
29. Downey LM, Keen TJ, Roberts E, et al. A new locus for autosomal dominant familial exudative vitreoretinopathy maps to chromosome 11p12-13. *Am J Hum Genet.* 2001;68:778–81
30. Duke JR. The role of cholesterol in the pathogenesis of Coats' disease. *Trans Am Ophthalmol Soc.* 1963;61:492–544
31. Eagle RC. *Eye Pathology: An Atlas and Text.* Philadelphia, PA, Wolters Kluwer Health/Lippincott Williams & Wilkins; 2011
32. Edward DP, Mafee MF, Garcia-Valenzuela E, et al. Coats' disease and persistent hyperplastic primary vitreous. Role of MR imaging and CT. *Radiol Clin North Am.* 1998;36:1119–31, x
33. Egerer I, Tasman W, Tomer TT. Coats disease. *Arch Ophthalmol.* 1974;92:109–12
34. Eisenberg L, Castillo M, Kwock L, et al. Proton MR spectroscopy in Coats disease. *AJNR Am J Neuroradiol.* 1997;18:727–9
35. Elliot AJ, Harris GS. The present status of the diagnosis and treatment of periphlebitis retinae (Eales' disease). *Can J Ophthalmol.* 1969;4:117–22
36. Entezari M, Ramezani A, Safavizadeh L, et al. Resolution of macular edema in Coats' disease with intravitreal bevacizumab. *Indian J Ophthalmol.* 2010;58:80–2
37. Farkas TG, Potts AM, Boone C. Some pathologic and biochemical aspects of Coats' disease. *Am J Ophthalmol.* 1973;75:289–301
38. Fox KR. Coats' disease. *Metab Pediatr Ophthalmol.* 1980;4:121–4
39. Galluzzi P, Venturi C, Cerase A, et al. Coats disease: Smaller volume of the affected globe. *Radiology.* 2001;221:64–9
40. Gass JD. Cavernous hemangioma of the retina. A neuro-oculo-cutaneous syndrome. *Am J Ophthalmol.* 1971;71:799–814
41. Gass JD, Oyakawa RT. Idiopathic juxtafoveolar retinal telangiectasis. *Arch Ophthalmol.* 1982;100:769–80
42. Ghazi NG, Al Shamsi H, Larsson J, et al. Intravitreal triamcinolone in Coats' disease. *Ophthalmology.* 2012;119:648–9
43. Glaser BM, Vidaurri-Leal J, Michels RG, et al. Cryotherapy during surgery for giant retinal tears and intravitreal dispersion of viable retinal pigment epithelial cells. *Ophthalmology.* 1993;100:466–70
44. Goel N, Kumar V, Seth A, et al. Role of intravitreal bevacizumab in adult onset Coats' disease. *Int Ophthalmol.* 2011;31:183–90
45. Gomez Morales A. Coats' disease. Natural history and results of treatment. *Am J Ophthalmol.* 1965;60:855–65
46. Gomori JM, Grossman RI, Shields JA, et al. Ocular mr imaging and spectroscopy: an ex vivo study. *Radiology.* 1986;160:201–5
47. Green WR. Bilateral Coats' disease. Massive gliosis of the retina. *Arch Ophthalmol.* 1967;77:378–83
48. Gujar SK, Gandhi D. Congenital malformations of the orbit. *Neuroimaging Clin N Am.* 2011;21:585–602, viii
49. Gurwin EB, Fitzsimons RB, Sehmi KS, et al. Retinal telangiectasis in facioscapulohumeral muscular dystrophy with deafness. *Arch Ophthalmol.* 1985;103:1695–700
50. Guyton JS, McGovern FH. Diathermy coagulation in the treatment of angiomatosis retinae and of juvenile Coats' disease: Report of two cases. *Am J Ophthalmol.* 1943;26:675
51. Haik BG. Advanced Coats' disease. *Trans Am Ophthalmol Soc.* 1991;89:371–476
52. Haik BG, Saint Louis L, Smith ME, et al. Computed tomography of the nonrhegmatogenous retinal detachment in the pediatric patient. *Ophthalmology.* 1985;92:1133–42
53. Haik BG, Saint Louis L, Smith ME, et al. Magnetic resonance imaging in the evaluation of leukocoria. *Ophthalmology.* 1985;92:1143–52
54. Harris GS. Coats' disease, diagnosis and treatment. *Can J Ophthalmol.* 1970;5:311–20
55. He YG, Wang H, Zhao B, et al. Elevated vascular endothelial growth factor level in coats' disease and possible therapeutic role of bevacizumab. *Graefes Arch Clin Exp Ophthalmol.* 2010;248:1519–21
56. Henkind P, Morgan G. Peripheral retinal angioma with exudative retinopathy in adults (Coats's lesion). *Br J Ophthalmol.* 1966;50:2–11
57. Henry CR, Berrocal AM, Hess DJ, et al. Intraoperative spectral-domain optical coherence tomography in Coats' disease. *Ophthalmic Surg Lasers Imaging.* 2012;43:e80–4
58. Hiscott P, Mudhar H. Is vasoproliferative tumour (reactive retinal gliosis) part of the spectrum of proliferative vitreoretinopathy? *Eye (Lond).* 2009;23:1851–8
59. Howard GM, Ellsworth RM. Differential diagnosis of retinoblastoma. A statistical survey of 500 children. I. Relative frequency of the lesions which simulate retinoblastoma. *Am J Ophthalmol.* 1965;60:610–8

60. Imre G. Coats' disease and hyperlipemic retinitis. *Am J Ophthalmol.* 1967;64:726–33
61. Jaffe MS, Shields JA, Canny CL, et al. Retinoblastoma simulating Coats' disease: a clinicopathologic report. *Ann Ophthalmol.* 1977;9:863–8
62. Jonas JB, Holbach LM. Clinical-pathologic correlation in coats' disease. *Graefes Arch Clin Exp Ophthalmol.* 2001;239:544–5
63. Jumper JM, Pomerleau D, McDonald HR, et al. Macular fibrosis in coats disease. *Retina.* 2010;30:S9–14
64. Kaul S, Uparkar M, Mody K, et al. Intravitreal anti-vascular endothelial growth factor agents as an adjunct in the management of coats' disease in children. *Indian J Ophthalmol.* 2010;58:76–8
65. Kessner R, Barak A, Neudorfer M. Intraretinal exudates in coats' disease as demonstrated by spectral-domain OCT. *Case Report Ophthalmol.* 2012;3:11–5
66. Khan JA, Ide CH, Strickland MP. Coats'-type retinitis pigmentosa. *Surv Ophthalmol.* 1988;32:317–32
67. Kim J, Park KH, Woo SJ. Combined photodynamic therapy and intravitreal bevacizumab injection for the treatment of adult Coats' disease: a case report. *Korean J Ophthalmol.* 2010;24:374–6
68. Koozekanani DD, Connor TB Jr, Wiroszko WJ. Retcam II fluorescein angiography to guide treatment and diagnosis of coats disease. *Ophthalmic Surg Lasers Imaging*;2010:1–3
69. Kremer I, Nissenkorn I, Ben-Sira I. Cytologic and biochemical examination of the subretinal fluid in diagnosis of coats' disease. *Acta Ophthalmol (Copenh).* 1989;67:342–6
70. Kuwabara T, Cogan DG. Studies of retinal vascular patterns. I. Normal architecture. *Arch Ophthalmol.* 1960;64:904–11
71. Lam HD, Samuel MA, Rao NA, et al. Retinoblastoma presenting as coats' disease. *Eye (Lond).* 2008;22:1196–7
72. Laqua H, Wessing A. Peripheral retinal telangiectasis in adults simulating a vascular tumor or melanoma. *Ophthalmology.* 1983;90:1284–91
73. Leber T. Die aneurysmen der zentralarterie und ihrer verzweigungen. Retinaldegeneration bei multiplen miliaraneurysmen, in Saemisch T (ed) *Handbuch der Gesamten Augenheilkunde.* Leipzig, Wilhelm Engelmann; Ed. 2., 1915, pp 20–35
74. Leber T. Verber ein durch yorkommen multipler miliaraneurisi men charakterisierte form von retinaldegeneration. *Graefes Arch Clin Exp Ophthalmol.* 1912;81:1–14
75. Lin CJ, Hwang JF, Chen YT, et al. The effect of intravitreal bevacizumab in the treatment of coats disease in children. *Retina.* 2010;30:617–22
76. Lindau A. Zur frage der angiomatosis retinae und ihrer hirnkomplikationen. *Acta Ophthalmol.* 1927;4:193
77. Mafee MF, Aimbinder D, Afshani E, et al. The eye. *Neuroimaging Clin N Am.* 1996;6:29–59
78. Mafee MF, Goldberg MF, Greenwald MJ, et al. Retinoblastoma and simulating lesions: role of CT and MR imaging. *Radiol Clin North Am.* 1987;25:667–82
79. Manschot WA, de Bruyn WC. [Coats' disease]. *Ned Tijdschr Geneesk.* 1966;110:1684–5
80. McGettrick PM, Loeffler KU. Bilateral Coats' disease in an infant (a clinical, angiographic, light and electron microscopic study). *Eye (Lond).* 1987;1(Pt 1):136–45
81. McGrand JC. Photocoagulation in Coats' disease. *Trans Ophthalmol Soc UK.* 1970;90:47–56
82. Medlock RD, Shields JA, Shields CL, et al. Retinal hemangioma-like lesions in eyes with retinitis pigmentosa. *Retina.* 1990;10:274–7
83. Messmer E, Laqua H, Wessing A, et al. Nine cases of cavernous hemangioma of the retina. *Am J Ophthalmol.* 1983;95:383–90
84. Miyakubo H, Inohara N, Hashimoto K. Retinal involvement in familial exudative vitreoretinopathy. *Ophthalmologica.* 1982;185:125–35
85. Mrejen S, Metge F, Denion E, et al. Management of retinal detachment in Coats disease. Study of 15 cases. *Retina.* 2008;28:S26–32
86. Muftuoglu G, Gulkilik G. Pars plana vitrectomy in advanced Coats' disease. *Case Report Ophthalmol.* 2011;2:15–22
87. Nickerson SJ, Al-Dahmash SA, Shields CL, et al. Retinal vasoproliferative tumor with total retinal detachment managed with plaque radiotherapy. *Oman J Ophthalmol.* 2012;5:53–4
88. Nucci P, Bandello F, Serafino M, et al. Selective photocoagulation in coats' disease: ten-year follow-up. *Eur J Ophthalmol.* 2002;12:501–5
89. Othman IS, Moussa M, Bouhaimed M. Management of lipid exudates in Coats disease by adjuvant intravitreal triamcinolone: Effects and complications. *Br J Ophthalmol.* 2010;94:606–10
90. Pancurak J, Goldberg MF, Frenkel M, et al. Cavernous hemangioma of the retina. Genetic and central nervous system involvement. *Retina.* 1985;5:215–20
91. Pendergast SD, Trese MT. Familial exudative vitreoretinopathy. Results of surgical management. *Ophthalmology.* 1998;105:1015–23
92. Perez-Campagne E, Wolfensberger TJ. Reemergence of dormant coats disease after 30 years. *Eur J Ophthalmol.* 2012;22:509–12
93. Pesch KJ, Meyer-Schwickerath G. [Light coagulation in morbus Coats and Leber's retinitis]. *Klin Monbl Augenheilkd.* 1967;151:846–53
94. Pruett RC. Retinitis pigmentosa: clinical observations and correlations. *Trans Am Ophthalmol Soc.* 1983;81:693–735
95. Ramasubramanian A, Shields CL. Bevacizumab for Coats' disease with exudative retinal detachment and risk of vitreoretinal traction. *Br J Ophthalmol.* 2012;96:356–9
96. Reese AB. Telangiectasis of the retina and Coats' disease. *Am J Ophthalmol.* 1956;42:1–8
97. Robitaille JM, Zheng B, Wallace K, et al. The role of Frizzled-4 mutations in familial exudative vitreoretinopathy and Coats disease. *Br J Ophthalmol.* 2011;95:574–9
98. Salazar FG, Lamiell JM. Early identification of retinal angiomas in a large kindred von Hippel-Lindau disease. *Am J Ophthalmol.* 1980;89:540–5
99. Scheffler AC, Berrocal AM, Murray TG. Advanced Coats' disease. Management with repetitive aggressive laser ablation therapy. *Retina.* 2008;28:S38–41
100. Schuman JS, Lieberman KV, Friedman AH, et al. Senior-loten syndrome (familial renal-retinal dystrophy) and Coats' disease. *Am J Ophthalmol.* 1985;100:822–7
101. Scimeca G, Magargal LE, Augsburg JJ. Chronic exudative ischemic superior temporal-branch retinal-vein obstruction simulating Coat's disease. *Ann Ophthalmol.* 1986;18:118–20
102. Senft SH, Hidayat AA, Cavender JC. Atypical presentation of Coats disease. *Retina.* 1994;14:36–8
103. Shields CL, Shields JA, Barrett J, et al. Vasoproliferative tumors of the ocular fundus. Classification and clinical manifestations in 103 patients. *Arch Ophthalmol.* 1995;113:615–23
104. Shields JA, Decker WL, Sanborn GE, et al. Presumed acquired retinal hemangiomas. *Ophthalmology.* 1983;90:1292–300
105. Shields JA, Parsons HM, Shields CL, et al. Lesions simulating retinoblastoma. *J Pediatr Ophthalmol Strabismus.* 1991;28:338–40
106. Shields JA, Reichstein D, Mashayekhi A, et al. Retinal vasoproliferative tumors in ocular conditions of childhood. *J AAPOS.* 2012;16:6–9



107. Shields JA, Shields CL, Honavar SG, et al. Classification and management of Coats disease: the 2000 Proctor Lecture. *Am J Ophthalmol.* 2001;131:572–83
108. Shukla D, Chakraborty S, Behera UC, et al. Vitrectomy for epimacular membrane secondary to adult-onset coats' disease. *Ophthalmic Surg Lasers Imaging.* 2008;39:239–41
109. Sims KB. NDP-related retinopathies, in Pagon RA, Bird TD, Dolan CR, et al (eds) *GeneReviews.* Seattle, WA, University of Washington; 1993
110. Singh AD, Ahmad NN, Shields CL, et al. Solitary retinal capillary hemangioma: lack of genetic evidence for von Hippel-Lindau disease. *Ophthalmic Genet.* 2002;23:21–7
111. Singh AD, Nouri M, Shields CL, et al. Treatment of retinal capillary hemangioma. *Ophthalmology.* 2002;109:1799–806
112. Singh AD, Nouri M, Shields CL, et al. Retinal capillary hemangioma: a comparison of sporadic cases and cases associated with von Hippel-Lindau disease. *Ophthalmology.* 2001;108:1907–11
113. Smirniotopoulos JG, Bargallo N, Mafee MF. Differential diagnosis of leukokoria: radiologic-pathologic correlation. *Radiographics.* 1994;14:1059–79, quiz 1081–2
114. Smith SE, Mullen TE, Graham D, et al. Norrie disease: extraocular clinical manifestations in 56 patients. *Am J Med Genet A.* 2012;158A:1909–17
115. Sohn EH, Michaelides M, Bird AC, et al. Novel mutation in *pank2* associated with retinal telangiectasis. *Br J Ophthalmol.* 2011;95:149–50
116. Spallone A, Carlevaro G, Ridling P. Autosomal dominant retinitis pigmentosa and Coats'-like disease. *Int Ophthalmol.* 1985;8:147–51
117. Spitznas M, Jousseaume F, Wessing A. Treatment of Coats' disease with photocoagulation. *Albrecht Von Graefes Arch Klin Exp Ophthalmol.* 1976;199:31–7
118. Spitznas M, Jousseaume F, Wessing A, et al. Coat's disease. An epidemiologic and fluorescein angiographic study. *Albrecht Von Graefes Arch Klin Exp Ophthalmol.* 1975;195:241–50
119. Spitznas M, Meyer-Schwickerath G, Stephan B. The clinical picture of Eales' disease. *Albrecht Von Graefes Arch Klin Exp Ophthalmol.* 1975;194:73–85
120. Steidl SM, Hirose T, Sang D, et al. Difficulties in excluding the diagnosis of retinoblastoma in cases of advanced Coats' disease: a clinicopathologic report. *Ophthalmologica.* 1996;210:336–40
121. Stergiou PK, Symeonidis C, Dimitrakos SA. Coats' disease: treatment with intravitreal bevacizumab and laser photocoagulation. *Acta Ophthalmol.* 2009;87:687–8
122. Sun Y, Jain A, Moshfeghi DM. Elevated vascular endothelial growth factor levels in coats disease: Rapid response to pegaptanib sodium. *Graefes Arch Clin Exp Ophthalmol.* 2007;45:1387–8
123. Takei Y. Origin of ghost cell in Coats' disease. *Invest Ophthalmol.* 1976;15:677–81
124. Tekin NF, Saatci AO, Kavukcu S. Vascular tortuosity and Coats'-like retinal changes in facioscapulohumeral muscular dystrophy. *Ophthalmic Surg Lasers.* 2000;31:82–3
125. Theodossiadis GP. Some clinical, fluorescein-angiographic, and therapeutic aspects of Coats' disease. *J Pediatr Ophthalmol Strabismus.* 1979;16:257–62
126. Toomes C, Downey LM, Bottomley HM, et al. Identification of a fourth locus (*EVR4*) for familial exudative vitreoretinopathy (*FEVR*). *Mol Vis.* 2004;10:37–42
127. Tripathi R, Ashton N. Electron microscopical study of Coat's disease. *Br J Ophthalmol.* 1971;55:289–301
128. Venkatesh P, Mandal S, Garg S. Management of coats disease with bevacizumab in 2 patients. *Can J Ophthalmol.* 2008;43:245–6
129. von Hippel E. Ueber eine seltene erkrankung der netzhaut. *Arch f Augenh.* 1904;59:83
130. Wang KY, Cheng CK. A combination of intravitreal bevacizumab injection with tunable argon yellow laser photocoagulation as a treatment for adult-onset Coats' disease. *J Ocul Pharmacol Ther.* 2011;27:525–30
131. Warburg M. Norrie's disease. *Trans Ophthalmol Soc UK.* 1965;85:391–408
132. Warburg M. Norrie's disease. *J Ment Defic Res.* 1968;12:247–51
133. Warburg M. Norrie's disease—differential diagnosis and treatment. *Acta Ophthalmol (Copenh).* 1975;53:217–36
134. Woods AC, Duke JR. Observations on Coats' disease. *Trans Ophthalmol Soc UK.* 1962;82:105–21
135. Yannuzzi LA, Bardal AM, Freund KB, et al. Idiopathic macular telangiectasia. *Arch Ophthalmol.* 2006;124:450–60
136. Zhao T, Wang K, Ma Y, et al. Resolution of total retinal detachment in Coats' disease with intravitreal injection of bevacizumab. *Graefes Arch Clin Exp Ophthalmol.* 2011;49:1745–6